



Cutaneous Mycoses in Chameleons Caused by the Chryso sporium Anamorph of *Nannizziopsis vriesii* (Apinis) Currah

Author(s): Jean A. Paré, Lynne Sigler, D. Bruce Hunter, Richard C. Summerbell, Dale A. Smith and Karen L. Machin

Source: *Journal of Zoo and Wildlife Medicine*, Vol. 28, No. 4 (Dec., 1997), pp. 443-453

Published by: [American Association of Zoo Veterinarians](#)

Stable URL: <http://www.jstor.org/stable/20095688>

Accessed: 02/02/2015 19:24

Your use of the JSTOR archive indicates your acceptance of the Terms & Conditions of Use, available at <http://www.jstor.org/page/info/about/policies/terms.jsp>

JSTOR is a not-for-profit service that helps scholars, researchers, and students discover, use, and build upon a wide range of content in a trusted digital archive. We use information technology and tools to increase productivity and facilitate new forms of scholarship. For more information about JSTOR, please contact support@jstor.org.



American Association of Zoo Veterinarians is collaborating with JSTOR to digitize, preserve and extend access to *Journal of Zoo and Wildlife Medicine*.

<http://www.jstor.org>

CUTANEOUS MYCOSES IN CHAMELEONS CAUSED BY THE *CHRYSOSPORIUM* ANAMORPH OF *NANNIZZIOPSIS VRIESII* (APINIS) CURRAH

Jean A. Paré, D.M.V., D.V.Sc., Lynne Sigler, M.Sc., D. Bruce Hunter, D.V.M., M.Sc.,
Richard C. Summerbell, Ph.D., Dale A. Smith, D.V.M., D.V.Sc., and
Karen L. Machin, B.Sc., D.V.M.

Abstract: A dermatophyte-like fungus was isolated from skin biopsies of three different species of captive chameleon in which fungal elements had been observed by histologic examination. An adult Parson's chameleon (*Chamaeleo parsonii*) presented with vesicles that became crusty brown lesions on the limbs and body. Skin biopsies revealed fungal hyphae in the affected epidermis and underlying dermis. The lesions regressed fully after oral administration of itraconazole. An adult jewel chameleon (*Chamaeleo lateralis*) from the same private collection presented with localized black skin lesions and died while being treated with itraconazole. A pulmonary granuloma was also present in this chameleon at autopsy. Cultures obtained from skin and lung lesions yielded the same fungus. A third isolate was obtained from a skin biopsy of a Jackson's chameleon (*Chamaeleo jacksoni*) with deep ulcerative cutaneous lesions located at the base of the tail. The fungus, in all three cases, has been identified as the *Chrysosporium* anamorph of *Nannizziopsis vriesii*, a poorly known ascomycetous species recorded previously from the skin of a lizard and from soil, on the basis of its keratinolytic activity, resistance to cycloheximide, strongly restricted growth at 37°C, formation of clavate or pyriform single-celled or two-celled aleurioconidia, and alternate and fission arthroconidia.

Key words: Chameleon, *Chamaeleo*, dermatomycosis, *Chrysosporium*, *Nannizziopsis vriesii*, itraconazole.

INTRODUCTION

Reviews of diseases in reptiles belonging to the order Squamata (Lacertilia and Serpentes) indicate that mycoses of the skin may be underreported, that causative agents are often inadequately identified, and that it is often difficult to evaluate whether the isolated fungus is present as a contaminant or is involved in a pathologic process.^{4,5,20,28,30} Cutaneous mycoses in humans and other mammals are usually caused by dermatophytes, but most reports of skin infection concerning lacertilians and ophidians have been attributed to a wide variety of soil fungi, including members of the genera *Aspergillus*,^{8,15,32,43} *Candida*,^{32,43} *Cladosporium*,¹¹ *Fusarium*,^{4,19,43} *Geotrichum*,^{2,4,19,25,27,41} *Monilia*,¹⁴ *Mucor*,^{20,32,40,43} *Paecilomyces*,¹¹ *Penicillium*,³² *Rhizopus*,⁴³ *Trichoderma*,^{19,32} *Trichosporon*,^{32,43} *Ulocladium*,⁴³ and unidentified taxa.^{4,20} Fungi that have been associated with skin

lesions in the Chamaeleonidae are *Mucor circinelloides* in a two-lined chameleon (*Chamaeleo bi-taeniatus*) and a common chameleon (*C. chamaeleon*),⁴³ *Candida guillermundii* in a Fischer's chameleon (*C. fischeri*) and a Jackson's chameleon (*C. jacksoni*),⁴³ an unidentified yeast in a Meller's chameleon (*C. melleri*),⁴ *Fusarium oxysporum* in two flap-necked chameleons (*C. dilepis*),^{4,43} and *Aspergillus* sp. in a Jackson's chameleon.¹⁵

Dermatophytoses are fungal infections of the keratinized tissues caused by a group of closely related keratinophilic fungi known as dermatophytes.³⁹ Dermatophyte species belonging to the genera *Trichophyton* and *Microsporum* commonly cause skin disease in both humans and animals, but true dermatophytosis has rarely been recorded in lacertilians^{4,17,32} and, to our knowledge, never in chameleons. The paucity of reports linking dermatophytes with cutaneous disease prompted Austwick and Keymer to state that "The susceptibility of reptile skins to fungal infection clearly does not lie in the direct invasion of the keratinized layers by dermatophytes . . ." ⁴ Reports of dermatophytoses in ophidians are also rare. *Trichophyton mentagrophytes* was recovered from a ball python (*Python regius*) with dermal lesions,¹⁵ but most other reports involve species of keratinophilic fungi of soil origin that may be isolated as contaminants and for which demonstration of a pathogenic role is difficult. *Trichophyton terrestre*, a geophilic fungus that is usually considered nonpathogenic, has been isolated from the scales of an apparently healthy

From the Department of Pathology, Ontario Veterinary College, University of Guelph, Guelph, Ontario N1G 2W1, Canada (Paré, Hunter, Smith); the University of Alberta Microfungus Collection and Herbarium, Devonian Botanic Garden, Edmonton, Alberta T6G 2E1, Canada (Sigler); the Ontario Ministry of Health, Laboratory Services Branch, 81 Resources Road, Etobicoke, Ontario M9P 3T1, Canada (Summerbell); and the Department of Veterinary Internal Medicine, Western College of Veterinary Medicine, University of Saskatchewan, Saskatoon, Saskatchewan S7N 5B4, Canada (Machin). Present address (Paré): Calgary Zoo, Box 3036, Station B, Calgary, Alberta T2M 4R8, Canada.

boa constrictor (*Boa constrictor*)⁴ and was associated with progressive digital necrosis in eastern blue-tongued skinks (*Tiliqua scincoides*), in which numerous hyphae were seen histologically,¹⁷ but a causal relationship could not be ascertained. Although fungal elements could be seen histologically, whether they were primary etiologic agents or secondary invaders of devitalized tissue could not be determined. An unknown *Trichophyton* species was isolated from the cutis and muscles of a day gecko (*Phelsuma* sp.) with multiple nodular skin lesions.³² This was one of a group of recently imported geckos showing similar cutaneous lesions. A survey of keratinophilic fungi from Australia demonstrated the presence of *Microsporium cookei* and *Chrysosporium* species from epidermal scales of a clinically normal monitor lizard (*Varanus* sp.) and from the skink *Egernia bungana*.³¹ *Chrysosporium* sp. was isolated from nodular subcutaneous lesions in a corn snake (*Elaphe guttata guttata*),^{4,5,23} and *C. keratinophilum*, *C. tropicum*, and *Chrysosporium* sp. have been cited as agents of dermatomycoses in lizards (*Varanus salvator*, *Lacerta viridis*, and *Crotaphytus* sp.).^{9,43} One report identified *C. keratinophilum* as an agent of deep infection involving the lung and stomach in two iguanas.⁴²

This report describes three cases of skin infection in captive chameleons. The same fungus was isolated in pure culture, and fungal elements were demonstrated by histopathology of biopsied lesions in two of the cases. The causative agent was identified as the *Chrysosporium* anamorph (mitotic stage) of *Nannizziopsis vriesii* (Apinis) Currah, a poorly known ascomycetous fungus first described under the name *Rollandina vriesii* Apinis³ for an isolate obtained from the skin and lungs of a lizard (*Ameiva* sp.). The fungus was disposed subsequently as *Arachnotheca vriesii* (Apinis) Samson³⁸ and later as *Nannizziopsis vriesii*.¹² *Nannizziopsis vriesii* is a member of the order Onygenales, family Onygenaceae,¹² and records to date indicate that it is known only from the original lizard isolate and one other from soil in California. Variability in microscopic features suggests that this species could be misidentified or confused with dermatophyte species such as *Trichophyton mentagrophytes* or *T. terrestre* or with geophilic, keratinophilic *Chrysosporium* or *Malbranchea* species. Its propensity to form fission arthroconidia could suggest *Geotrichum*.

CASE REPORTS

Case 1

An adult male Parson's chameleon (*Chamaeleo parsonii*) from a private collection was presented

to the Veterinary Teaching Hospital of the Ontario Veterinary College for evaluation of a skin lesion of the left stifle. The lizard had been purchased from a pet store 2 mo earlier, quarantined for 6 wk, and treated twice, at 10-day intervals, with fenbendazole (Safe Guard, Hoechst Canada Inc., Regina, Saskatchewan, Canada), 50 mg/kg orally, as ascarid eggs had been seen on a fecal flotation. The lizard was fed crickets dusted with a multivitamin powder. It ate well, although it refused any other kind of food, and drank well. Housing and husbandry met the minimal standards recommended for maintenance of chameleons in captivity,¹³ except for inadequate ultraviolet radiation exposure. The lizard was presented in late September, 45 days after weather made it impossible for the owner to take it outside on a daily basis.

The chameleon weighed 368 g and was alert, responsive, and in good body condition. Abnormalities were restricted to a 1 × 0.5 cm ovoid, depressed area of gray devitalized skin on the cranio-lateral aspect of the left stifle. A thin crevice visible along the rim of the lesion exposed the dermis, suggesting that a large vesicle had ruptured and collapsed. Within a week, two small gray vesicles, 3–4 mm in diameter, appeared on the lateral aspect of the right elbow. The chameleon was anesthetized with isoflurane (AErrane, Anaquest, Mississauga, Ontario, Canada) delivered through an induction chamber and then through a face mask. Biopsies were taken from the edge of the stifle lesion and from one of the elbow lesions using a 3-mm disposable skin biopsy punch (Acu-Punch 3mm, Acuderm Inc., Fort Lauderdale, Florida 33307, USA). The resulting skin defects were closed with a single simple suture using polydioxanone monofilament (PDS 3-0, Ethicon, Inc., Somerville, New Jersey 08876, USA). The other vesicle was incised, and the clear exudate it contained was collected and submitted for bacteriology. The patient was discharged from the hospital with oral trimethoprim-sulfamethoxazole (Apo-Sulfatrim, Apotex Inc., Toronto, Ontario, Canada), 30 mg/kg once daily, pending the results of the biopsy. The culture was negative for any bacterial agent. Poor sectioning of biopsied tissues made the histopathologic interpretation difficult, but marked heterophilic infiltration of the epidermis and dermis was noted. One week after initiation of antibiotic therapy, the lizard was again presented with numerous new lesions on all limbs, the flanks, and tail. These were roughly circular, focal, protruding brown encrustations that measured several millimeters in diameter. The initial lesion on the stifle had thickened, and the devitalized skin had become a large thick scab. The

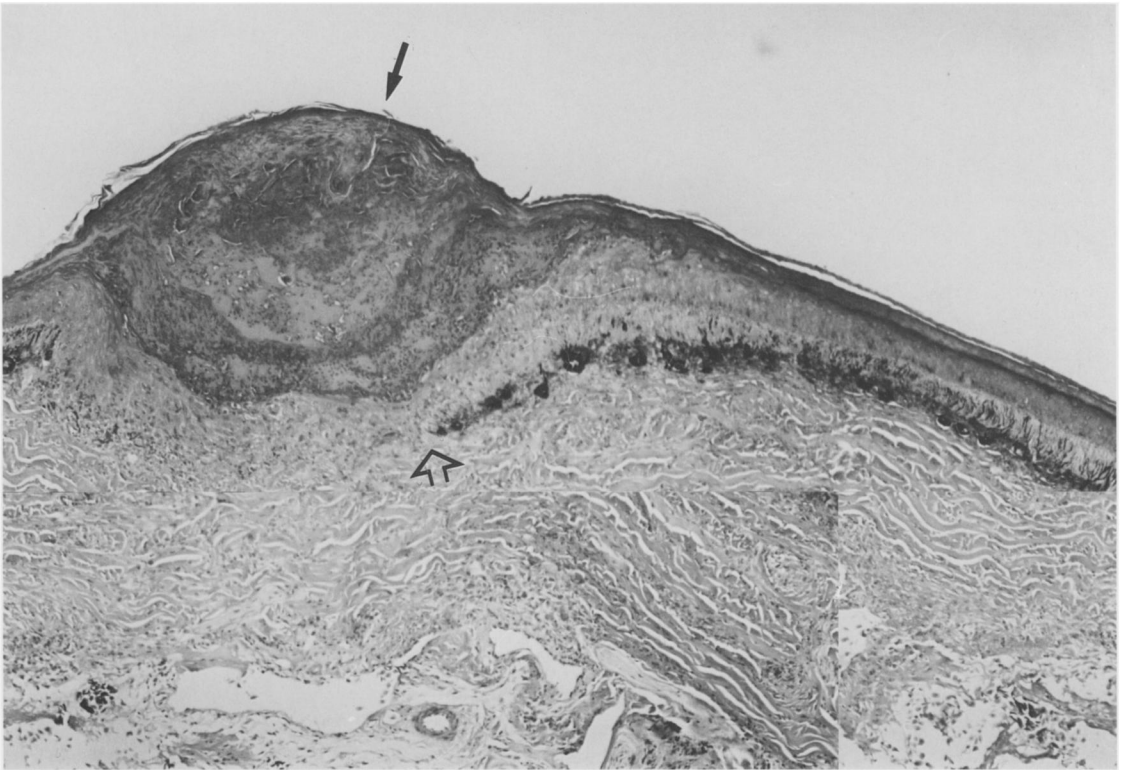


Figure 1. Skin from a Parson's chameleon. Focal hyperkeratosis and coagulation necrosis of the stratum corneum are visible (arrow). Note the discontinuity of the dermal melanophore layer (open arrow). H&E, $\times 40$.

lizard was anesthetized and three more skin biopsies were taken. Blood was collected from the ventral tail vein and submitted for a complete blood cell count.

A leukocytosis (34.5×10^9 cells/L, suggested reference range in lacertilians: $12\text{--}22.5 \times 10^9$ cells/L⁷) and a lymphocytosis (59%, or 20.3×10^9 cells/L) were the prominent hematologic findings. Occasional microfilariae also were noted. On hematoxylin-eosin-stained sections, there was focal hyperkeratosis with necrosis of the stratum corneum and heterophilic infiltration of the subjacent epidermis and dermis (Fig. 1). Aggregates of macrophages and diffuse heterophil infiltration within the deeper layers of the dermis were consistent with a deep heterophilic cellulitis. A periodic acid-Schiff stain of the same section revealed fungal hyphae within the affected stratum corneum and adjacent epithelium (Fig. 2) and deeper layers of the dermis. Hyphae were partly refractile and septate with minimal branching. A frozen biopsy submitted for culture yielded a slow-growing *Trichophyton*-like fungus. The isolated fungus was referred to the University of Alberta Microfungus Collection for further study.

An oral liquid suspension of itraconazole (Janssen Pharmaceutica, Beerse, Belgium; 10 mg/mL) was added to the treatment regimen (10 mg/kg once daily for 21 days). No new lesions appeared, and the preexisting ones regressed partially and dried up. Antibiotic therapy was discontinued 1 week prior to cessation of antifungal administration, 21 days after the initial visit. The owner noted that the chameleon was more reluctant to accept the itraconazole than the antibiotic. The lizard's appetite declined over the last few days of medication, and the owner was required to hand-feed and, weeks later, force-feed the lizard. The patient was reevaluated 45 days from the initial visit. Many skin lesions had disappeared, and no new lesion had appeared; however, a general loss of condition was noticed. The lizard appeared to favor the left hind leg and would not grasp perches as easily as it did previously. Radiographs suggested hepatomegaly. The packed cell volume (18%) had dropped from initial value (23%) but was still within the suggested reference range for lacertilians (16–45%).⁷ Elevated serum levels of creatinine kinase (10,898 U/L) and aspartate aminotransferase activity (>800 U/L) were the

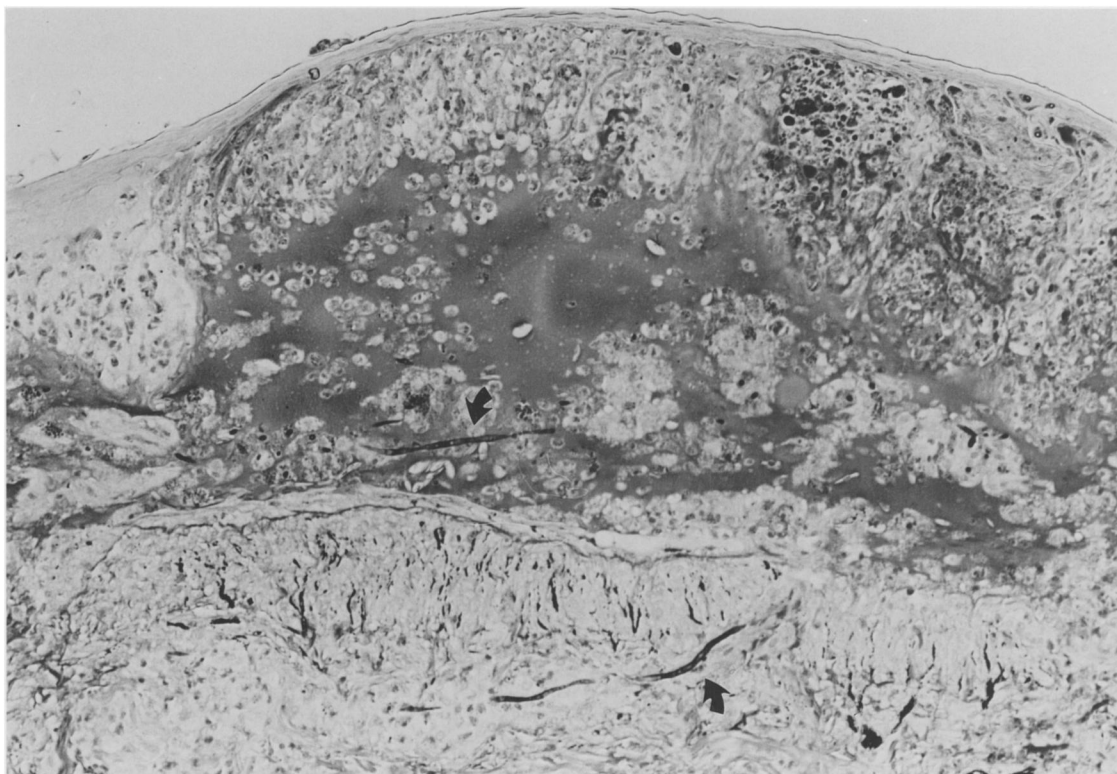


Figure 2. Coagulation necrosis of the stratum corneum of a Parson's chameleon cutaneous epithelium. Note the fungal hyphae in the epidermis and dermis (arrows). PAS, $\times 100$.

only biochemical abnormalities noted. Microfilariae were again visualized on the blood smear.

The chameleon's appetite increased and its general body condition improved in the months that followed. After ecdysis, only the scab on the stifle remained. The chameleon died about 1 year after initial presentation. Autopsy indicated that death was due to cholecystitis and septicemia, but no evidence of mycosis was seen.

Case 2

An adult male jewel chameleon (*Chamaeleo lateralis*) purchased from the same pet store by the same collector was presented for evaluation. The tiny lizard was alert and active. It weighed 17 g and appeared in good flesh. There were two localized areas of black discoloration of the skin. One measured approximately 2 mm and involved the right upper lip at the mucocutaneous junction. The second lesion, slightly larger, was located on the dorsal aspect of the digits of the left hind foot (Fig. 3). A thin layer of exfoliated squames partially covered the pedal lesion, and a sample was submitted for fungal culture. The chameleon was sent home on itraconazole oral suspension, at a dosage of 10

mg/kg once daily for 21 days. Six days after initiation of therapy, the lizard was found dead in the vivarium. Postmortem examination revealed a granulomatous mass located in the caudal lung and extending to the wall of the coelomic cavity and to the kidney. Histologic examination revealed the presence of a severe deep heterophilic cellulitis extending from the skin surface into the muscles of the foot. Periodic acid–Schiff stain showed many hyphae in the affected tissues. Numerous hyphae were also seen within the granuloma involving the lung and kidney (Fig. 4). A fungus identical to the isolate from case 1 was cultured from the pedal squames, the lungs, and the kidney and was forwarded to the University of Alberta for further evaluation.

Case 3

An adult male Jackson's chameleon was presented to the Veterinary Teaching Hospital of the Western College of Veterinary Medicine with a 2-cm round scab on the left side, at the base of the tail. The lizard weighed 100 g, was alert and active. Blood analysis revealed a leukocytosis ($32 \times 10^9/L$) with a lymphocytosis (83%, or $26.6 \times 10^9/L$). El-

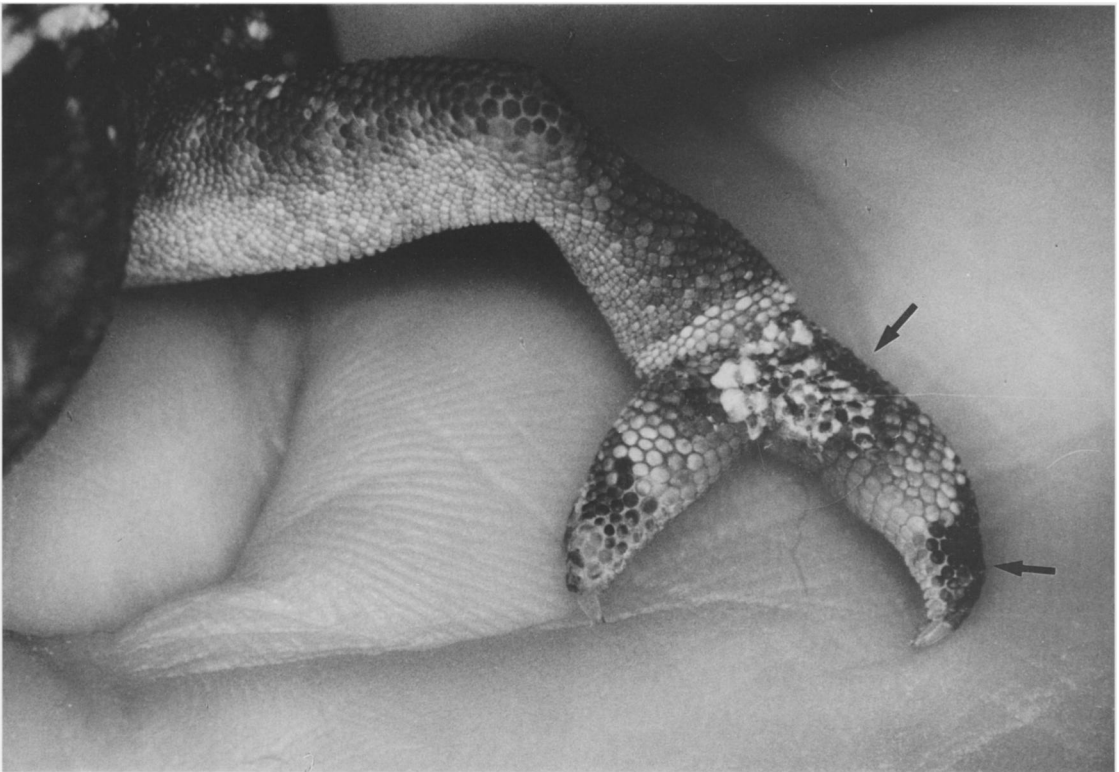


Figure 3. Black discoloration of the skin on the dorsal aspect of the left hind foot and digits of a jewel chameleon (arrows). Note the exfoliative white squames.

evated packed cell volume (57%) and total solids (15 g/dl) values suggested dehydration. The area was debrided and cultured. Large numbers of *Clostridium* sp. were isolated as well as a fungus identified as a *Trichophyton* sp. This isolate was identical to that of cases 1 and 2, and a frozen biopsy was later forwarded to the University of Alberta. Fluids were administered intracoelomically, the wound was bandaged, and the lizard was sent home on a trimethoprim-sulfamethoxazole oral suspension (Novotrimel, Novopharm Limited, Calgary, Alberta, Canada; 15 mg/kg b.i.d.) for 14 days. Ketoconazole (Nizoral, Janssen Pharmaceutica Inc., Mississauga, Ontario, Canada; 25 mg/kg, Q2D, p.o. for 4 wk) was added to the regimen when fungal culture results were obtained. The lizard was re-examined 2 wk later as a hemipenis had prolapsed through a ventral extension of the wound. The lizard was anesthetized with ketamine hydrochloride (Ketaset, Ayerst Laboratories, Montreal, Quebec, Canada; 20 mg/kg), and the prolapsed hemipenis was gently cleansed with saline and was reduced through the hole in the ventral tail base. Closure of the wound was performed using 4-0 Novofil (Davis & Geck, Cyanamid Medical Device Company Inc.,

Anyang, Korea). A second culture of the wound yielded *Enterococcus faecalis* and *Staphylococcus* sp. The antibiotics were changed to an amoxicillin-clavulanic acid oral suspension (Clavamox drops, Smith Kline Beecham Animal Health Inc., Mississauga, Ontario, Canada; 22 mg/kg b.i.d.), and ketoconazole was continued. The chameleon was presented 2 wk later with a recurrence of the hemipenis prolapse. The area of necrotic skin was almost circumferential around the base of the tail. The hemipenis was removed surgically under ketamine anesthesia, and tolnaftate (Tinactin, Schering Canada Inc., Pointe Claire, Quebec, Canada) was to be applied topically on a daily basis by the owner. This chameleon was then lost to follow-up.

Mycological examination

Isolates from cases 1 and 2 were deposited in the University of Alberta Microfungus Collection as UAMH 7582 and 7583. The chameleon isolates were compared with known strains of *Nannizziosis vriesii* in all tests. Isolates of *N. vriesii* included the ex-type (culture derived from the type specimen) (UAMH 3713 = ATCC 22444 = CBS 407.71 = IMI 149994), which had been isolated from the

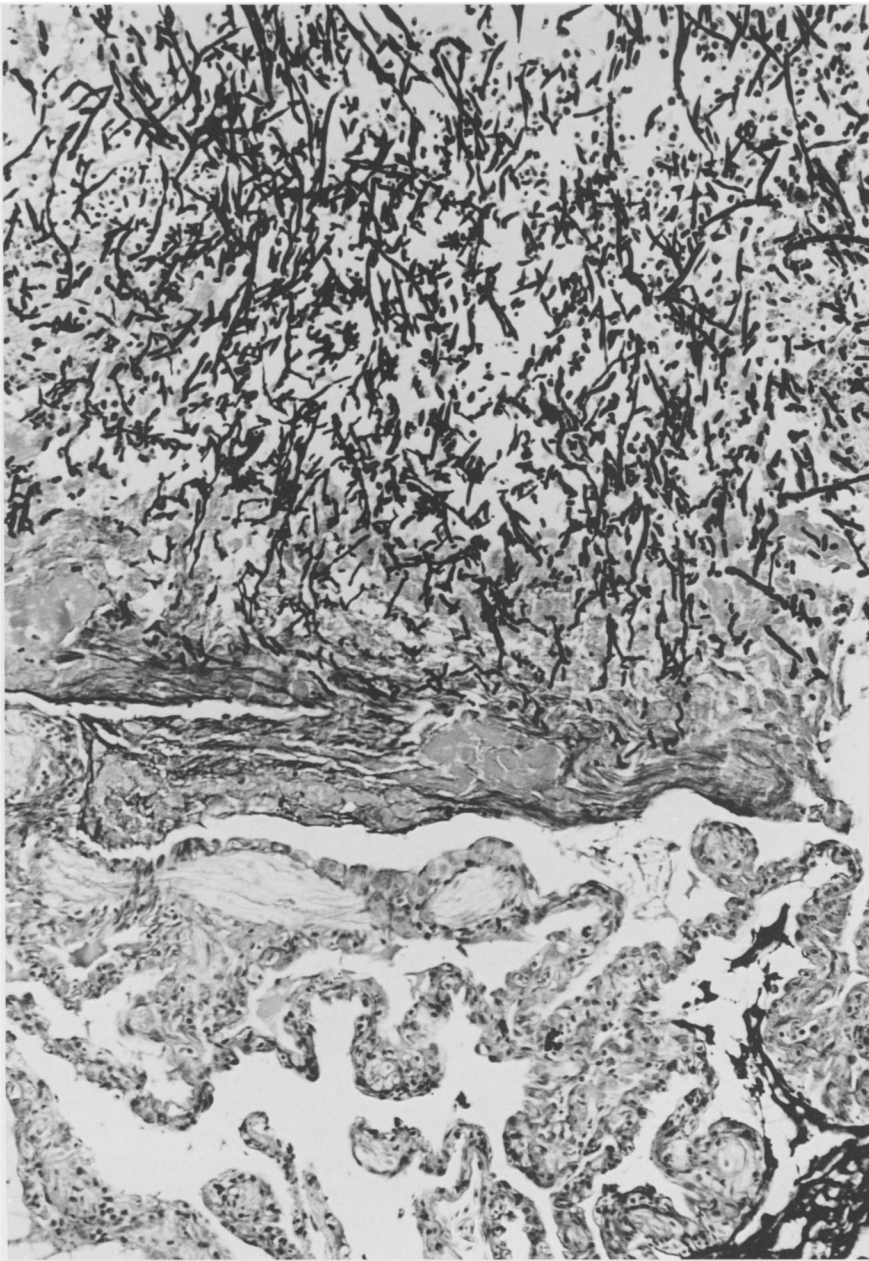


Figure 4. *Chrysosporium* anamorph of *Nannizziaopsis vriesii* hyphae in a necrotic focus in the lung of a jewel chameleon. PAS, $\times 100$.

skin and lungs of a lizard (*Ameiva* sp.) in Netherlands by G. A. de Vries, and an isolate from soil in southern California (UAMH 3526). The case 3 isolate (UAMH 7861) was obtained later and not included in all tests.

For observation of colonial features and growth rates, isolates were grown at 25°C on phytone yeast extract agar (Becton Dickinson Microbiology Sys-

tems, Cockeysville, Maryland 21030, USA), a modification of Sabouraud dextrose medium that has been used for the study of *Chrysosporium* species,^{10,35,37} and potato dextrose agar (Difco Laboratories, Detroit, Michigan 48232-7058, USA). Media used for the promotion of sporulation and development of sexual stages included 10% Pablum cereal agar²² and oatmeal agar²² with incubation at 22° or 25°C for 2–3

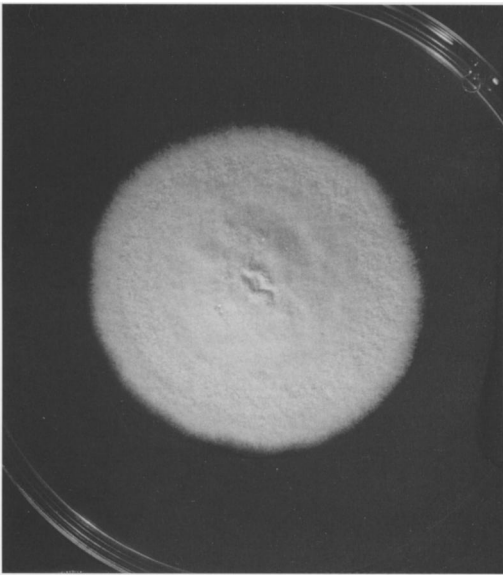


Figure 5. Colony of *Chrysosporium* anamorph of *Nanizziopsis vriesii* on potato dextrose agar after 21 days at 25°C (UAMH 7583). $\times 0.8$.

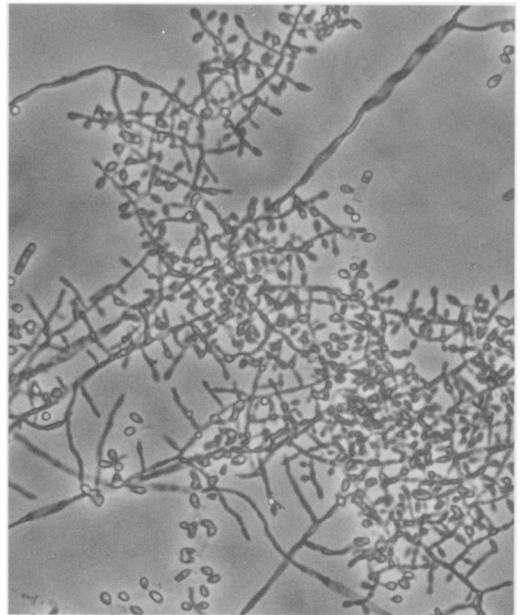


Figure 6. Pyriform or clavate sessile conidia formed on branched hyphae (UAMH 7582). $\times 580$.

mo. In a subsequent attempt to obtain ascomata (sexual fruiting bodies), isolates were grown at 30°C \pm 2°C on Takashio agar,²² amended with 5% yeast extract, and on oatmeal agar. Terminology for colony colors follows Kornerup and Wanscher.²⁴ Because of similarities between some *Chrysosporium* species and dermatophyte species, isolates also were subjected to a battery of physiologic tests performed commonly in the dermatophyte diagnostic. Isolates were evaluated for their responses in the following tests: 1) growth, pH change, and clearing of milk solids on Bromcresol purple–milk solids–glucose agar^{21,22,36} compared to growth on Sabouraud dextrose agar (Difco); 2) urease activity in Christensen's urea broth²²; 3) tolerance to cycloheximide at 400 $\mu\text{g ml}^{-1}$ by recording growth rates on mycosel agar^{22,33}; 4) tolerance to salt at concentrations of 0, 3, 5, and 7% and measured as the sodium chloride concentration causing >50% growth inhibition at 14 days^{1,22}; 5) requirements for vitamins thiamine and inositol by comparing growth on Trichophyton agars 2, 3, and 4 with growth on vitamin-free casamino acids agar (Trichophyton agar 1) (Difco); 6) ability to grow at 37°C; and 7) ability to digest hairs after 2–3 wk incubation.³⁵ Descriptions of microscopic features are based mainly on slide culture preparations.³⁴

Colonies (Fig. 5) of the three chameleon isolates are moderately fast growing, reaching diameters of 4–4.5 cm on phytone yeast extract and potato dextrose agar after 21 days at 25° or 30°C; growth rates were the same on mycosel agar. Colonies are yel-

lowish white to pale yellow (3A2/4A3); flat or slightly raised in the center (umbonate); dense, except thin at margin; sometimes with concentric zones of denser growth; powdery; and often showing fine fissures or cracks, with or without small droplets of clear exudate on the surface, reverse uncolored. Colonies of the two *N. vriesii* isolates are similar, except that they grow slightly faster, reaching diameters of 4.5–5.5 cm after 21 days. Conidia (aleurioconidia) (Fig. 6) are pyriform (teardrop-shaped) or clavate (club-shaped), single-celled or rarely two-celled, and are borne sessile (i.e., formed directly on the sides of the hyphae, not on stalks) or at the ends of branched fertile hyphae. Lateral and terminal conidia are 3–12.5 μm long and 1.5–2.5 μm wide but are commonly 3–6 μm in length and single-celled. Portions of the hyphae frequently fragment to form arthroconidia, which are either alternate (i.e., separated from each other by a cell or cells that undergo lytic disintegration) or in chains and separated by fission at the septum (i.e., schizolytic dehiscence). Arthroconidia (Fig. 7) are cylindrical and are 4–9 μm long and 1.5–3.5 μm wide. A feature common to all isolates is the formation of undulate, solitary, sparsely septate lateral branches (Fig. 8). Rarely, these branches fragment to form arthroconidia.

The chameleon isolates failed to fruit (form sexual fruiting bodies) under any growth conditions, but isolates of *N. vriesii* formed fertile ascomata

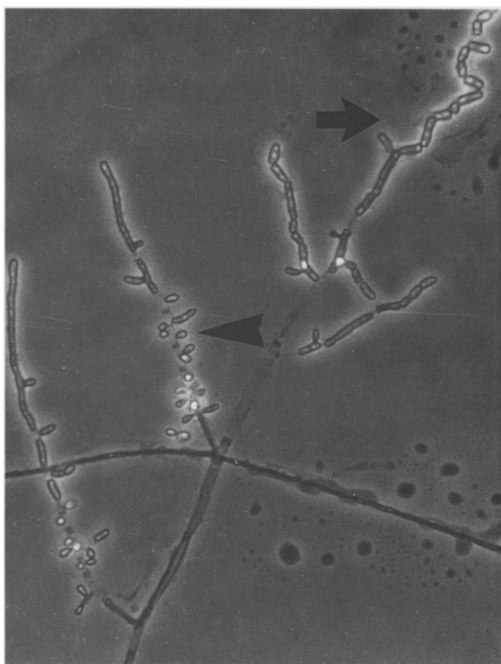


Figure 7. Fertile hyphae bearing sessile conidia (arrowhead) and fragmenting to form arthroconidia (arrow) (UAMH 7582). $\times 460$.

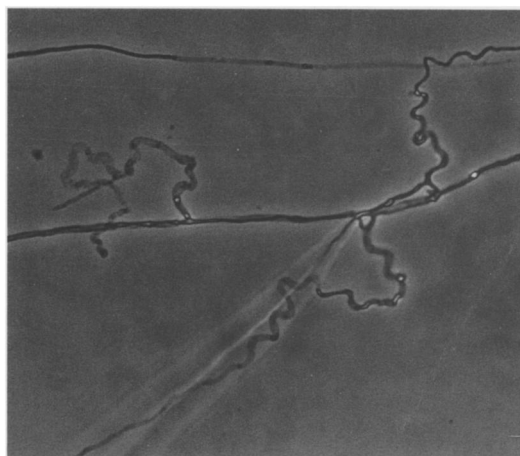


Figure 8. Undulate lateral branches (UAMH 7861). $\times 460$.

characteristic for the species^{3,12} when grown on Takashio and oatmeal agars at 30°C. The *N. vriesii* isolates appeared initially to have lost sexual vigor, since they failed to form ascomata even after several months at lower temperature of incubation, but once sexual reproduction was reestablished, isolates fruited also at 25°C on cereal agar.

In the special tests, the chameleon isolates and the two isolates of *N. vriesii* shared the following features: 1) strong urease activity, usually by 5–7 days; 2) digestion of hairs with formation of perforating bodies; 3) greater than 50% growth inhibition at 37°C; 4) no requirements for vitamins thiamine or inositol; 5) inhibition by salt at a concentration of 3% (concentration causing >50% reduction of colony diameter). On Bromcresol purple–milk solids–glucose agar after 11 days, the chameleon isolates showed moderate to profuse growth, no change in pH or trace acidity indicated by a color change to faint yellow, and strong clearing of the milk solids beyond the margin of the colony. On this medium, the *N. vriesii* isolates showed profuse growth, some clearing of the milk solids behind the colony, and no change in pH or trace alkalinity indicated by a color change to faint purple within the clear zone.

DISCUSSION

Regarding the taxon as “reminiscent” of *Arthroderma* Berkeley, Apinis described *Rollandina vriesii* in the genus *Rollandina* Patouillard based on a single isolate from the skin and lung of an *Ameiva* species.³ Ascomata of *N. vriesii* lack appendages and are composed of anastomosed asperulate hyphae that are constricted at the septa and in which individual cells are fairly uniform in shape. Ascomata of members of the genus *Arthroderma* (family Arthrodermataceae, Onygenales) differ in that they are composed of hyphae in which the cells are typically dumbbell-shaped or ossiform (bone-shaped), and hyphae may terminate in tightly coiled appendages.¹² Apinis also described an associated anamorph or asexual stage as “pyriform or cylindrical to clavate conidia that are formed singly on vegetative hyphae of the *Sporotrichum* or *Chrysosporium* type, or in chains (*Oidium* type) 2–3 \times 3–8 μm in diameter.”³ Later workers rejected *Rollandina* as a nomen confusum, and Currah transferred *R. vriesii* to the new genus *Nannizziopsis* Currah within the family Onygenaceae (Onygenales), primarily on the basis of ascospore shape and wall ornamentation.¹² Ascospores of *N. vriesii* are globose, measuring 2.5–3 μm in diameter, and punctate-reticulate, whereas ascospores of members of the Arthrodermataceae are oblate (round in face view, flattened in side view) and smooth. The anamorph has been accommodated in *Chrysosporium*.

Since none of the chameleon isolates has fruited (i.e., formed fertile ascomata), they cannot be identified with certainty as *N. vriesii*; however, characteristics of their conidia and physiology and their isolation from lizards suggest a close relationship.

Similar features include 1) limited thermotolerance (restricted growth at 37°C); 2) the pyriform or clavate shape of the conidia, which are occasionally 1-septate and borne sessile rather than on stalks; 3) the presence of lateral curved or undulate branches; 4) the tendency to form arthroconidia that are either alternate or in chains; 5) strong keratinolytic activity; and 6) similar physiologic features, including urease activity, cycloheximide tolerance, absence of requirements for vitamins, and tolerance for salt at a concentration of 3%. The chameleon isolates differed from *N. vriesii* in having strongly powdery colonies that grew slightly more slowly, and in their growth patterns on Bromcresol purple–milk solids–glucose agar medium, with a clearing of milk solids beyond the margin of the colony. The chameleon isolates form a subset of a larger group of similar fungi obtained from skin lesions in members of the order Squamata and currently under study by two of us (LS, RCS). Additional investigations of relationships will include molecular analyses.

The isolation of the same fungus from three chameleons with cutaneous lesions in which fungal hyphae were observed by histology firmly establishes this fungus as an etiologic agent of infection. The involvement of the fungus in deep mycosis as seen in case 2 is unusual and further establishes a link with *N. vriesii*, which was isolated also from both skin and lung. It seems likely that this chameleon fungus has been reported previously, but correlations are difficult because many reports fail to illustrate the fungus, and the isolates from these cases rarely are deposited into culture collections. Previous reports concerning *Trichophyton* species^{4,15,17,32} or *Chrysosporium* species^{4,5,9,23,42,43} could have been dealing with the same fungus. Two of the chameleon isolates were identified initially by one laboratory as *T. verrucosum* and by a second laboratory as *T. terrestre*, but they differed slightly in in vitro growth characteristics. The sessile conidia of *N. vriesii* are reminiscent of microconidia of species of *Trichophyton* such as *T. mentagrophytes* or *T. terrestre*, but *N. vriesii* fails to develop macroconidia typical of *Trichophyton* species. Moreover, the development of characteristic fruiting bodies at 30°C on certain media confirms their distinction. Several reports link reptilian skin infections to *Geotrichum candidum*,^{2,4,19,25,27,41} a yeast-like hyphomycete in which hyphae fragment to form cylindrical arthroconidia. Although *G. candidum* seems unlikely to be confused with the *Chrysosporium* anamorph of *N. vriesii* when the characteristic lateral conidia predominate, there may be a preponderance of fission arthroconidia under some cultural conditions. Further mycological evaluation

of isolates involved in reptilian skin infections would be useful in delineating etiologic agents.

It is difficult to determine where or when the chameleons became infected. The authors were informed that another chameleon, bought by a different party from the same source as chameleons 1 and 2 and around the same time, had been diagnosed elsewhere with fungal dermatitis and died shortly thereafter. It is likely that the case 1 and 2 lizards were from the same shipment and were harboring the organism at the time of purchase. This fungus may be part of the normal skin flora of chameleons. Unsanitary captive conditions, malnutrition, high humidity, overcrowding, and poor water quality are thought to predispose reptiles to fungal disease.²⁰ Parson's chameleons and jewel chameleons originate from Madagascar, and Jackson's chameleons from Africa.²⁶ Parson's chameleons are notoriously short-lived in captivity, with one source stating a longevity record of 11 months.⁶ We speculate that the stresses of capture, quarantine, and shipping contributed to undermine the immunity of these lizards to fungal infection. It is probable that pulmonary infection occurred by inhalation from a contaminated, poorly ventilated environment; however, hematogenous spread cannot be precluded. Microfilaremia in the Parson's and intestinal trematodiasis in the jewel chameleon also may have contributed to lower hosts' resistance.

Lesions reported in reptiles with skin mycoses are variable and often poorly described. These include loosening of the horny part of the scales, nodules, abrasions, plaques, crusts, granulomas, and focal necrotic ulcers, perhaps reflecting different stages of disease progression. Focal black or gray discoloration of the skin was observed in cases 1, 2, and 3. Bullous or vesicular lesions ("blister disease") in reptiles are common but are usually associated with bacteria, rarely with fungi.¹⁶ Affected animals are often kept under suboptimal conditions.¹⁶ The vesicular aspect of the early skin lesions in case 1 suggests that fungal disease must be considered by the clinician when confronted with a bullous or vesicular skin condition in a chameleon.

The use of itraconazole in reptiles has not been well documented. Itraconazole is a triazole antifungal with a broader spectrum of activity, greater efficacy at lower dose, and less toxic potential than the more frequently used ketoconazole.²⁹ Itraconazole, like ketoconazole, inhibits ergosterol biosynthesis by binding to fungal, but not mammalian, cytochrome P-450 enzymes. Ergosterol is an essential component of the fungal cell membrane. When its synthesis is disrupted, a defective membrane results; intracellular accumulation of ergosterol pre-

cursors may also contribute to eventual cell rupture.²⁹ Itraconazole does not suppress cortisol synthesis in humans and dogs²⁹ and thus should not interfere with the animal's response to stress. Itraconazole has been shown to be effective against various agents of systemic mycoses, yeasts, dermatophytes, and some protozoans. The dose of 10 mg/kg/day was based on the suggested dosage for the dog (1–10 mg/kg/day).²⁹ In case 1, therapy with itraconazole appeared to resolve the lesions, although transient anorexia and loss of condition were noted. Elevations in the creatinine kinase and aspartate aminotransferase activity remain unexplained. The possibility of ongoing muscular damage from fungal growth under the seemingly quiescent stifle lesion was considered. Itraconazole therapy was not reinstated because of potential hepatotoxicity in a patient with a palpably and radiographically enlarged liver. It is likely that the stress of daily handling and medicating was also detrimental to this animal's appetite and general health. The role of itraconazole in the demise of the chameleon in case 2 is undetermined, as hepatotoxicity, the main adverse effect, was not identified. The animal died too soon to assess the efficacy of the antifungal therapy. The use of ketoconazole in case 3 did not seem to alter significantly the progression of the lesions, although the role played by the fungus is unclear.

Raising and maintaining the lizard's environment temperature in the upper zone of the species' preferred optimal temperature range should be generally beneficial and, given *N. vriesii*'s limited thermotolerance, may be therapeutic.

Acknowledgments: We thank Arlene Flis and Linda Abbott (University of Alberta Microfungus Collection and Herbarium) for assistance with culture and photography, and Debbie Bateman and Gisela Kittler (Ontario Veterinary College Microbiology Laboratory) and Jamie and Lynda Horgan for their cooperation and commitment. L. S. acknowledges financial assistance from the Natural Sciences and Engineering Research Council of Canada.

LITERATURE CITED

1. Abbott, S. P., L. Sigler, R. McAleer, D. A. McGough, M. G. Rinaldi, and G. Mizell. 1995. Fatal cerebral mycoses caused by the ascomycete *Chaetomium strumarium*. *J. Clin. Microbiol.* 33: 2692–2698.
2. Abou-Gabal, M., and R. Zenoble. 1980. Subcutaneous mycotic infection of a Burmese python snake. *Mykosen* 23: 627–631.
3. Apinis, A. E. 1970. Concerning *Rollandina*. *Trans. Br. Mycol. Soc.* 55: 499–502.
4. Austwick, P. K. C., and I. F. Keymer. 1981. Fungi and actinomycetes. *In: Cooper, J. E., and O. F. Jackson (eds.). Diseases of the Reptilia*, vol 1. Academic Press, Harcourt Brace Jovanovich, London, England. Pp. 193–231.
5. Austwick, P. K. C. 1982. Some mycoses of reptiles. VII Congress International Society for Human and Animal Mycology. Pp. 383–384.
6. Barten, S. L. 1993. The medical care of iguanas and other common pet lizards. *In: Vet. Clin. North Am. Small Anim. Pract.: Exotic Pet Medicine I.* 23(6): 1213–1249.
7. Beynon, P. H., M. P. C. Lawton, and J. E. Cooper (eds.). 1992. *Manual of Reptiles*. British Small Animal Veterinary Association, Sherdington, Cheltenham, Gloucestershire, U.K., Appendix III, p. 220.
8. Borst, G. H. A., C. Vroeghe, F. G. Poelma, P. Zwart, W. J. Strik, and J. C. Peters. 1972. Pathological findings on animals in the Royal Zoological Gardens of the Rotterdam zoo during the years 1963, 1964 and 1965. *Acta Zoologica et Pathologica Antverpiensia* 56: 3–19.
9. Bryant, W. M. 1982. Mycotic dermatitis in a collection of desert lizards. *Am. Assoc. Zoo Vet. Proc. Annu. Meet. New Orleans, Louisiana.* P. 4.
10. Carmichael, J. W. 1962. *Chrysosporium* and some other aleuriosporic Hyphomycetes. *Can. J. Bot.* 40: 1137–1173.
11. Cork, S. C., and P. H. G. Stockdale. 1994. Mycotic disease in the common New Zealand gecko (*Hoplodactylus maculatus*). *N. Z. Vet. J.* 42: 144–147.
12. Currah, R. S. 1985. Taxonomy of the Onygenales: Arthrodermataceae, Gymnoasceae, Myxotrichaceae and Onygenaceae. *Mycotaxon* 24: 1–216.
13. de Vosjoli, P. 1990. *The General Care and Maintenance of True Chameleons, part I, Husbandry*. Advanced Vivarium Systems, Lakeside, California.
14. Dillberger, J., and M. Abou-Gabal. 1979. Mycotic dermatitis in a black ratsnake. *Mykosen* 22: 187–190.
15. Frye, F. L. 1981. *Biomedical and Surgical Aspects of Captive Reptile Husbandry*. Veterinary Medicine Publishing Co., Edwardsville, Kansas.
16. Frye, F. L. 1991. *Biomedical and Surgical Aspects of Captive Reptile Husbandry*. Krieger Publishing Co., Malabar, Florida.
17. Hazell, S. L., G. J. Eamens, and R. A. Perry. 1985. Progressive digital necrosis in the eastern blue-tongued skink, *Tiliqua scincoides* (Shaw). *J. Wildl. Dis.* 21: 186–188.
18. Jacobson, E. 1978. Diseases of the respiratory system in reptiles. *Vet. Med/Small Anim. Clin.* 73: 1169–1175.
19. Jacobson, E. R. 1980. Necrotizing mycotic dermatitis in snakes: clinical and pathologic features. *J. Am. Vet. Med. Assoc.* 177: 838–841.
20. Jacobson, E. R. 1980. Mycotic diseases of reptiles. *In: Montali, R. J., and G. Migaki (eds.). The Comparative Pathology of Zoo Animals*. Smithsonian Institution, Washington, D.C. Pp. 283–290.
21. Kane, J., L. Sigler, and R. C. Summerbell. 1987. Improved procedures for differentiating *Microsporium per-*

- sicolor* from *Trichophyton mentagrophytes*. J. Clin. Microbiol. 25: 2249–2452.
22. Kane, J., R. C. Summerbell, L. Sigler, S. Krajdén, and G. Land. 1997. Laboratory Handbook of Dermatophytes: A Clinical Guide and Laboratory Manual of Dermatophytes and Other Filamentous Fungi from Skin, Hair and Nails. Star Publishing Co., Belmont, California.
23. Keymer, I. F. 1976. Report of the pathologist, 1973 and 1974. J. Zool. London 178: 470–471.
24. Kornerup, A., and J. H. Wanscher. 1978. Methuen Handbook of Color, 3rd ed. Eyre Methuen Ltd., London, U.K.
25. Marcus, L. C. 1981. Veterinary Biology and Medicine of Captive Amphibians and Reptiles. Lea and Febiger, Philadelphia, Pennsylvania.
26. Martin, J., and A. Wolfe. 1992. Masters of Disguise: A Natural History of Chameleons. Facts on File, New York, New York.
27. McKenzie, R. A., and P. E. Green. 1976. Mycotic dermatitis in captive carpet snakes. J. Wildl. Dis. 12: 405–408.
28. Migaki, G. 1980. Mycotic diseases in captive animals—a mycopathologic overview. In: Montali, R. J., and G. Migaki (eds.). The Comparative Pathology of Zoo Animals. Smithsonian Institution, Washington, D.C. Pp. 267–273.
29. Mundell, A. C. 1990. New therapeutic agents in veterinary dermatology. Vet. Clin. North Am. Small Anim. Med. 20, 6: 1541–1556.
30. Page, L. A. 1966. Diseases and infections of snakes: a review. Bull. Wildl. Dis. 2: 111–125.
31. Rees, R. G. 1967. Keratinophilic fungi from Queensland. I. Isolations from animal hair and scales. Sauraudia 5: 165–172.
32. Schildger, B. J., H. Frank, T. Göbel, and R. Weiss. 1991. Mycotic infections of the integument and inner organs in reptiles. Herpetopathologia 2: 81–97.
33. Sigler, L., J. L. Harris, D. M. Dixon, A. L. Flis, I. F. Salkin, M. Kemna, and R. A. Duncan. 1990. Microbiology and potential virulence of *Sporothrix cyanescens*, a fungus rarely isolated from blood and skin. J. Clin. Microbiol. 28: 1009–1015.
34. Sigler, L. 1992. Preparing and mounting slide cultures. In: Isenberg, H. D. (ed.). Clinical Microbiology Procedures Handbook. American Society for Microbiology, Washington, D.C. Sect. 6, p. 6.12.1–6.12.4.
35. Sigler, L. 1997. *Chrysosporium* and molds resembling dermatophytes. In: Kane, J., R. C. Summerbell, L. Sigler, S. Krajdén, and G. Land (eds.). Laboratory Handbook of Dermatophytes: A Clinical Guide and Laboratory Manual of Dermatophytes and Other Filamentous Fungi from Skin, Hair and Nails. Star Publishing Co., Belmont, California.
36. Summerbell, R. C., S. A. Rosenthal, and J. Kane. 1988. Rapid method for differentiation of *Trichophyton rubrum*, *Trichophyton mentagrophytes*, and related dermatophyte species. J. Clin. Microbiol. 26: 2279–2282.
37. Van Oorschot, C. A. N. 1980. A revision of *Chrysosporium* and allied genera. Stud. Mycol. 20: 1–89.
38. Von Arx, J. A. 1981. The Genera of Fungi Sporulating in Pure Culture, 3rd ed. J. Cramer, Vaduz, Liechtenstein.
39. Weitzman, I., J. Kane, and R. C. Summerbell. 1995. *Trichophyton*, *Microsporium*, *Epidermophyton*, and agents of superficial mycoses. In: Murray, P. R., E. J. Baron, M. F. Tenover, and R. H. Tenover (eds.). Manual of Clinical Microbiology, 6th ed. American Society for Microbiology, Washington, D.C. Pp. 791–809.
40. Werner, R., M. A. Balady, and G. J. Kolaja. 1978. Phycomycotic dermatitis in an eastern indigo snake. Vet. Med./Small Anim. Clin. 73: 362–363.
41. Wissman, M. A., and B. Parsons. 1993. Dermatophytosis of green iguanas (*Iguana iguana*). J. Small Exot. Anim. Med. 2(3): 133–136.
42. Zwart, P., F. G. Poelma, W. J. Strik, J. C. Peters, and J. J. W. Polder. 1968. Report on births and deaths occurring in the Gardens of the Royal Rotterdam Zoo during the years 1961 and 1962. Tijdschr. Diergeneesk. 93: 348–365.
43. Zwart, P., and H. D. Schröder. 1985. Mykosen. In: Ippen, R., H. D. Schröder, and K. Elze (eds.). Handbuch der Zoonosen, vol. 1. Akademie Verlag, Berlin, Germany.

Received for publication 15 March 1996.