

Review Article

Invasive *Scopulariopsis brevicaulis* infection in an immunocompromised patient and review of prior cases caused by *Scopulariopsis* and *Microascus* species

PETER C. IWEN*, STEPHANIE D. SCHUTTE*, DIANA F. FLORESCU†, RHONDA K. NOEL-HURST* & LYNNE SIGLER‡

*Department of Pathology and Microbiology, †Internal Medicine Section of Infectious Diseases, University of Nebraska Medical Center, Omaha, Nebraska, USA, and ‡Microfungus Collection and Herbarium, Devonian Botanic Garden, University of Alberta, Edmonton, Alberta, Canada

Scopulariopsis species and their *Microascus* teleomorphs are cosmopolitan fungi that are uncommonly associated with invasive disease. This report describes a case of fatal disseminated *Scopulariopsis brevicaulis* disease in a patient with diffuse large B cell lymphoma who underwent high-dose chemotherapy followed by a matched unrelated donor stem cell transplant. This case is compared with 32 prior cases of proven invasive *Scopulariopsis* (*Microascus*) infections reported in the literature. A focus of this report is the diagnostic methods utilized which included histopathology and culture with both micromorphologic and genotypic procedures employed to confirm the species identification.

Keywords *Scopulariopsis brevicaulis*, *Microascus*, histopathology, genomic, invasive mold, internal transcribed spacer region

Introduction

Scopulariopsis and *Microascus* species include both hyaline and dematiaceous mold forms and have a wide geographic distribution. They are commonly found in soil and air, and in plant litter, paper, wood, dung and animal remains [1,2]. These fungi belong to the ascomycete family Microascaceae, which also includes well known opportunistic pathogens within the genera *Scedosporium* and *Pseudallescheria* [1–3]. In all these fungi, the conidial structures appear first in culture and are used for primary identification. Ascospores, if produced, appear in isolates grown for longer periods, or on specialized culture media, or in mating tests; therefore isolates of *Microascus* species may not be recognized from immature cultures *in vitro*.

Although large numbers of species are listed for both *Scopulariopsis* and *Microascus* genera in online databases such as Mycobank (www.mycobank.org) and Index Fungorum (www.indexfungorum.org), many species have not been re-evaluated with modern methods. About 30 valid species are known for *Scopulariopsis* and about 25, which are known to produce sexual stages, are classified in the genus *Microascus*.

Scopulariopsis (*Microascus*) species are recognized as common causes of non-invasive infections including nondermatophytic onychomycosis [4–6], keratitis [7], and otomycosis [8]. Although uncommon, invasive disease can also occur in both immunocompetent and immunosuppressed patients and include infections such as endocarditis [9–14], sinusitis [15–18], brain abscess [19–21], deep cutaneous [22–28], localized pulmonary [29,30], and disseminated [8,31–38]. Among these various invasive infections where the etiological agent has been identified to the species level, four *Scopulariopsis* species (*S. acremonium*, *S. brevicaulis*, *S. brumptii*, and *S. candida*) and two *Microascus* species (*M. cirrosus* and *M. cinereus*) have been reported [9,11–16,18,19,21–35,37,38]. *Scopulariopsis*

Received 1 December 2011; Received in final revised form 27 February 2012; Accepted 11 March 2012

Correspondence: Peter C. Iwen, University of Nebraska Medical Center, Department of Pathology and Microbiology, 985900 Nebraska Medical Center, Omaha, Nebraska, 68198-5900, USA. Tel: +1 402 559 7774; Fax: +1 402 559 7799; E-mail: piwen@unmc.edu

brevicaulis (*Microascus brevicaulis*) is the most prevalent and significant species identified from both superficial and invasive infections.

We describe a case of disseminated infection caused by *S. brevicaulis* in a patient with diffuse large B-cell lymphoma who underwent high-dose chemotherapy and an allogeneic hematopoietic stem cell transplant and compare this case with those of invasive infection described in the literature. Emphasis is placed on the diagnostic criteria used to identify cases of invasive *Scopulariopsis* infection including histopathology, positive culture for *Scopulariopsis* (*Microascus* species), and laboratory methods used for confirmation identification of the species.

Materials and methods

Literature review

Published cases of invasive *Scopulariopsis* or *Microascus* infection were identified by a literature search of the PubMed database. Additionally, the references cited in these reports were reviewed to identify additional cases that did not appear in the PubMed database. All cases were reviewed for demographic characteristics to include age/gender, underlying disease, transplant type, organ(s) involved, culture positive specimen source(s), and fungal species. They were also reviewed for diagnostic methods used including histopathologic description (includes inflammatory response and fungal elements in tissue) and culture identification methods used (micromorphological and genotypic). Only those cases that met the criteria for 'proven invasive fungal disease' caused by molds as described by the consensus group of the European Organization for Research and Treatment of Cancer/Invasive Fungal Infections Cooperative Group and the National Institute of Allergy and Infectious Diseases Mycoses Study Group (EORTC/MSG) were included in this evaluation [39]. The criteria included 'histopathologic, cytopathologic, or direct microscopic examination of a specimen obtained by needle aspiration or biopsy in which hyphae or melanized yeast-like forms are seen accompanied by evidence of associated tissue damage' and 'recovery of a mold or "black yeast" by culture of a specimen obtained by a sterile procedure from a normally sterile and clinically or radiologically abnormal site consistent with an infectious disease process, excluding bronchoalveolar lavage fluid, a cranial sinus cavity specimen, and urine'. Therefore, cases where *Scopulariopsis* (*Microascus*) were isolated from the latter types of specimens with or without the cytological presence of fungus were excluded from further analysis, in accordance with the guidelines [39].

Present case diagnostic methods

Skin biopsy material, which was cultured on slants of Sabouraud dextrose agar containing chloramphenicol and gentamicin (SAB, Remel, Lenexa, KS) and incubated at 28–30°C, grew a moderately fast growing mold after 9 days incubation. The mold was identified by the in-house laboratory as *Scopulariopsis* species based on the powdery, pale brown colonies and production of conidia in chains from brush-like conidiophores. For sequencing of the internal transcribed spacer 2 (ITS2) region of the rRNA gene, the isolate was grown on SAB and DNA was extracted from mycelium following protocols as previously described [40]. The ITS2 gene target was amplified using the ITS3 and ITS4 primers [41] and the resultant product sequence was aligned using the Chromas pro analysis software, version 6.5 (Oxford Molecular Group, Inc., Campbell, Calif.). The resultant 272 base pair sequence was compared with sequences in the GenBank (National Center for Biotechnology Information, Washington, DC) using a nongapped advanced BLAST search.

Isolate and nucleotide sequence accession number

A sequence of the case isolate has been deposited in GenBank under accession number FJ176395. The case isolate cultured from skin was deposited as *Scopulariopsis brevicaulis* at the University of Alberta Microfungus and Herbarium (UAMH), Edmonton, Alberta, Canada, under accession number UAMH 10915.

Results

Case report

A 26-year-old male was diagnosed with diffuse large B cell lymphoma and treated initially with a standard combination of chemotherapeutic agents. He was referred to the Nebraska Medical Center with relapsed disease and follow-up with high-dose chemotherapy (HDC). He subsequently underwent an autologous stem cell transplant with a second relapse occurring 72 days later at which point salvage HDC was initiated. Eighty four days after the stem cell transplant, the patient underwent a matched unrelated donor (allogeneic) hematopoietic stem cell transplant (HSCT) (Day 0 post-HSCT) and was discharged from the hospital on Day 20 post-HSCT in stable condition with an absolute neutrophil count (ANC) that was > 500 cells per mm³. He was readmitted at Day 27 post HSCT with graft-versus-host disease of the skin and gastrointestinal tract. Over the next 38 days, the hospitalization was complicated by recurrent fevers, a small bowel obstruction, a viridans group *Streptococcus* bacteremia, recurrent BK virus

hemorrhagic cystitis, acute renal failure and respiratory decompensation requiring intubation. During this hospitalization, seven fungal blood cultures (BACTEC System MYCO/F lytic medium, BD Diagnostics, Sparks, MD) were collected and all remained negative. No neutropenia (ANC remained above 500 cells per mm³) was present. A bronchoscopy was performed on Day 65 post-HSCT with a diagnosis of diffuse alveolar hemorrhage subsequently treated with the immunosuppressant etanercept. On Day 68 post-HSCT, black skin lesions were first noted on the patient's torso and buttock. At this time, the patient was receiving immunosuppressants (mycophenolate mofetil, tacrolimus, steroids and etanercept), as well as oral prophylactic voriconazole (200 mg twice daily), trimethoprim/sulfamethoxazole and acyclovir since the HSCT. Punch biopsies of one lesion on the left gluteal area and one lesion on the left anterior chest were performed on Day 71 post-HSCT and submitted for histopathology and culture (bacterial, fungal, and viral). Histopathology of both biopsy samples stained with the Grocott-Gomori methenamine silver (GMS) stain and the hematoxylin and eosin (H&E) stain revealed the presence of numerous septate irregular hyphae with the presence of swollen thick-walled structures (Fig. 1) as well as invasion of the vascular space (Fig. 2). No pigmentation of the hyphae was noted on the H&E stain. A suspicion of probable invasive aspergillosis that was developing on voriconazole led to a change in antifungal therapy to micafungin (100 mg/day for 7 days) and amphotericin B lipid formulation (5 mg/kg/day for 7 days); however, the *Aspergillus* galactomannan test was negative. Additionally, all immunosuppressive agents were discontinued with the exception of tacrolimus which was kept to a minimal dose (0.34 mg/day). No bacterial or viral pathogens were detected in culture from the skin. The skin lesions continued to spread to the extremities and torso and

on Day 78 post-HSCT, the patient became hypotensive and died. An autopsy was declined by the family. Both of the skin punch biopsies from day 71 grew a mold after 9 days incubation subsequently identified as a *Scopulariopsis* species. Since the isolate was not isolated prior to death, no antifungal susceptibility testing was performed.

Sequence comparison analysis of the ITS2 region for the case isolate was done and showed at that time a > 98.5% similarity to four strains of *Scopulariopsis brevicaulis* in the GenBank database with a 100% query coverage (Accession No. AY625065, AJ853776, EU436681, and EU821476). The next closest species was *S. chartarum* at 88%. The micromorphological characteristics also confirmed the isolate as *S. brevicaulis*. Conidia were thick-walled, smooth to coarsely roughened, subglobose with a flattened base and rounded or slightly pointed tip and they were produced in chains from annellidic conidiogenous cells borne in branched clusters (Fig. 3). Colonies on potato dextrose agar (Difco, Becton Dickinson Co., Sparks, MD) were tan and coarsely powdery and reached a diameter of 2 cm at 30°C (1.5 cm at 35°C) after 7 days. The isolate was tolerant of cycloheximide as determined by its equivalent growth on medium containing cycloheximide. Subcultures on sporulation media were held for 6 weeks but no ascospores were observed.

Literature review

A review of the English literature since 1974 identified 38 cases reported as invasive or disseminated *Scopulariopsis* (*Microascus*) infections. Thirty-two of these met our criteria for inclusion as proven invasive *Scopulariopsis* infections as described in the methods. Six cases were considered valid but not further evaluated since none described microscopic analysis of the mold in tissue or had positive

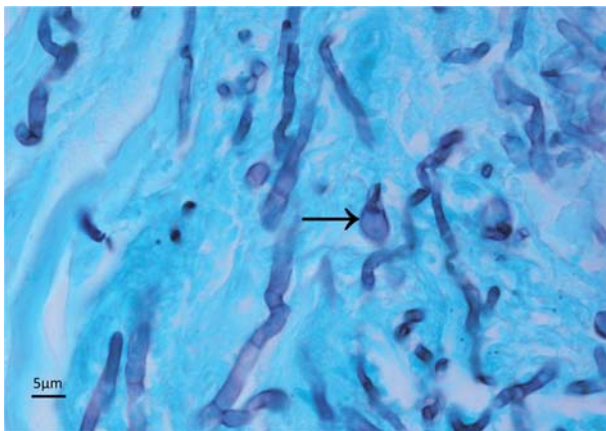


Fig. 1 Methenamine silver stain of skin showing septate, irregularly-shaped fungal hyphae and the presence of a swollen thick-walled structure (see arrow).

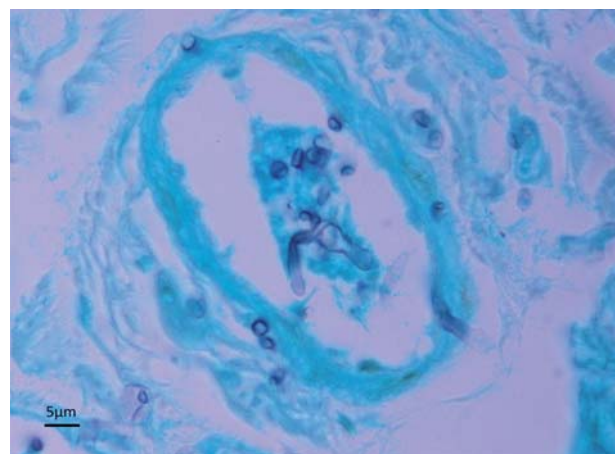


Fig. 2 Methenamine silver stain of skin showing fungal hyphae within a blood vessel.

cultures from normally sterile sites (5 cases were culture positive from a respiratory specimen [42–46] and 1 case described reproductive structures of *Scopulariopsis* in pleural fluid without a positive culture [47]). The reported cases as listed in Table 1 had a median age of 37 years (range 9–72) and represented 22 males and 10 females. Of these cases, 11 (34.4%) were identified in patients who had an underlying hematological malignancy (9 with leukemia and 1 each with non-Hodgkin's lymphoma and multiple myeloma). All of these patients had been treated with HDC for their diseases with eight undergoing a stem cell transplant (4 from bone marrow and 4 from hematopoietic sources). Seven of these patients developed a disseminated disease while four patients had a localized deep tissue infection recognized (2 involving sinus and 1 each involving cutaneous and pulmonary).

Of the 21 patients without a hematological malignancy, 15 had recognized underlying diseases including heart disorders (5 cases), complications due to solid organ transplant (3 cases), intravenous drug abuse (2 cases), complications due to bone marrow transplant for aplastic anemia (2 cases), chronic obstructive pulmonary disease (2 cases), and chronic granulomatous disease (1 case). Of these 21 patients, three had disseminated *Scopulariopsis* infection (Cases 9, 22, and 32) while the other 18 cases had reported localized invasive disease to the skin (7 cases), heart (6 cases), brain (2 cases), sinus (2 cases), and lung (1 case). Five patients with invasive *Scopulariopsis* disease did not have a recognized underlying condition described (Cases 1, 5, 7, 26, and 27). Four of these cases developed localized deep cutaneous infections (Cases 1, 7, 26, and 27). The most common specimen for diagnosis in all cases was from a deep cutaneous source (11 cases) followed by heart tissue (8 cases), and sinus tissue (5 cases). Multiple specimen sources were represented to verify disseminated disease in nine cases with blood reported as positive in four of these cases (Cases 3, 21, 31, and 32).

Table 2 describes the histopathological findings and methods used to confirm the identification. Twenty-nine of the prior cases had a histopathological description of tissue. The inflammatory responses, which were described for 14 cases (43.8%), showed granulomatous reactions and necrosis as the most common descriptions (8 and 7 cases, respectively). Twenty-one cases reported the presence of septate hyphal elements in tissue, while five indicated hyphae without mention of septations (Cases 17, 20, 22, 23, and 27) and three did not mention hyphae, but described the presence of other fungal elements. Tissues from 11 of the cases revealed additional structures described as 'vesicular swelling' (2 cases), 'conidia/spores' (2 cases), and one case each of 'large bulbous protrusions', 'conidia-like bodies', 'swollen thick-walled structures', 'moniliform fungal elements', 'globose cells', 'oblong cells in short chains',

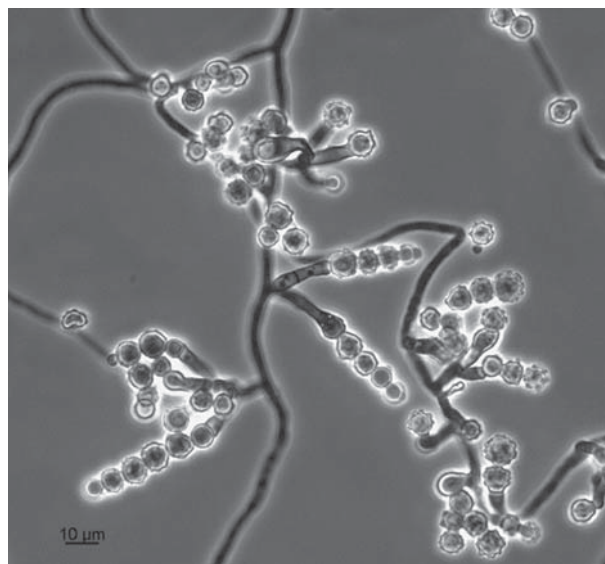


Fig. 3 Microscopic morphology of *Scopulariopsis brevicaulis* on PDA agar after 7 days at 30°C showing annellidic conidiogenous cells and rough-walled conidia in chains. Phase contrast microscopy was used.

'round non-budding bodies', and 'immature/mature perithecia'. In addition, eight cases described blood vessel invasion. Only one case described the presence of a brown pigment associated with the fungal elements (Case 2).

For culture identification methodology, 24 prior cases provided information on the micromorphologic identification methods used (Table 2). Although micromorphological characteristics were indicated for 10 cases, the features of the fungus were neither described nor illustrated and thus, the identity of the species involved cannot be confirmed. These include two of the cases reported as being caused by *S. acremonium* (Cases 14 and 25). Overall, the most common species identified was *S. brevicaulis* (13 cases) followed by *M. cinereus* (4 cases), *M. cirrosus* and *S. acremonium* (3 cases each), *S. brumptii* (2 cases), and *S. candida* (1 case). In six prior cases, only the *Scopulariopsis* genus was reported. Four of the more recent reports described the use of genomic sequencing methods to confirm the species identification (Cases 23, 26, 27, and 32). Three of these cases used the 28S rRNA target to identify species (2 *M. cirrosus* and 1 *S. brevicaulis*) and one case did not describe the genomic target (Case 27, *S. brevicaulis*).

Discussion

Invasive mold infections have become more common due to the increased practice of providing immunosuppressive therapies to treat a variety of conditions [48,49]. Although environmental molds such as *Aspergillus*, *Fusarium* and *Scedosporium* species are the more common molds

Table 1 Demographic characteristics of patients with proven invasive *Scopulariopsis* infection reported in the English literature.^a

Case No.	Age/Gender	Underlying Disease	Transplant Type	Disease Type ^b	Culture Positive Source(s)	Species ^c	Reference
1	36/F	None	None	Deep cutaneous	Ankle	<i>S. brevicaulis</i>	[26]
2	21/M	IVDA	None	Pulmonary	Lung	<i>S. brumptii</i>	[29]
3	17/M	CML	Allo-BM	Disseminated	Blood, brain, sinus, trachea	<i>Scopulariopsis</i> species	[8]
4	28/M	AML	None	Deep cutaneous	Ear	<i>Scopulariopsis</i> species	[8]
5	51/M	None	None	Sinus	Sinus	<i>M. cinereus</i>	[15]
6	40/M	AA	Allo-BM	Deep cutaneous	Great toe	<i>S. brevicaulis</i>	[25]
7	43/M	None	None	Deep cutaneous	Lip, lymph node	<i>S. brevicaulis</i>	[23]
8	12/F	NHL	None	Sinus	Sinus	<i>S. candida</i>	[18]
9	37/M	PSC	Liver	Disseminated	Brain, skin	<i>S. brumptii</i>	[21]
10	12/M	AML	Auto-BM	Disseminated	Multiple skin lesions	<i>M. cirrosus</i>	[32]
11	36/M	RF ^d	None	Cardiac	Heart	<i>S. brevicaulis</i>	[11]
12	9/F	CGD	None	Deep cutaneous	Arm, chest	<i>M. cinereus</i>	[24]
13	67/M	AS	None	Cardiac	Heart	<i>S. brevicaulis</i>	[14]
14	52/F	AML	None	Sinus	Sinus	<i>S. acremonium</i>	[16]
15	40/M	ND ^d	None	Cardiac	Heart	<i>M. cinereus</i>	[9]
16	72/M	COPD, DM	None	Sinus	Nasal septum	<i>Scopulariopsis</i> species	[17]
17	61/M	PBC	Liver	Deep cutaneous	Forearm	<i>S. brevicaulis</i>	[27]
18	21/F	AA	Allo-BM	Cerebral	Brain	<i>M. cinereus</i>	[19]
19	33/M	IVDA	None	Cerebral	Brain	<i>Scopulariopsis</i> species	[20]
20	38/F	RF ^d	None	Cardiac	Heart	<i>Scopulariopsis</i> species	[10]
21	10/M	AML	Allo-BM	Disseminated	Heart, lungs, kidneys, thorax, skin, blood	<i>S. brevicaulis</i>	[35]
22	63/M	COPD	Lung	Disseminated	Heart, thyroid gland, kidneys, lungs, stomach	<i>S. acremonium</i>	[38]
23	49/M	AML	Allo-BM	Pulmonary	Lung	<i>M. cirrosus</i>	[30]
24	67/F	RF ^d	None	Cardiac	Heart	<i>S. brevicaulis</i>	[12]
25	50/F	MM	Allo-HSC	Disseminated	Brain, sinus	<i>S. acremonium</i>	[31]
26	42/F	None	None	Deep cutaneous	Skin	<i>S. brevicaulis</i>	[22]
27	19/M	None	None	Deep cutaneous	Skin	<i>S. brevicaulis</i>	[28]
28	56/M	CML	Allo-HSC	Disseminated	Lung, skin	<i>Scopulariopsis</i> species	[36]
29	38/F	AML	Allo-HSC	Disseminated	Multiple skin lesions, stool, sputum	<i>S. brevicaulis</i>	[34]
30	43/M	AML	Auto-HSC	Disseminated	Multiple skin lesions	<i>S. brevicaulis</i>	[37]
31	58/M	MI ^d	None	Cardiac	Heart, blood	<i>S. brevicaulis</i>	[13]
32	36/M	CF	Heart, lung	Disseminated	Peritoneal blood clots, blood, pleural fluid, intrapericardial fluid	<i>M. cirrosus</i>	[33]
33	26/M	NHL	Allo-HSC	Disseminated	Multiple skin lesions	<i>S. brevicaulis</i>	PR

Abbreviations: AML, acute myelogenous leukemia; CML, chronic myelogenous leukemia; MM, multiple myeloma; NHL, nonHodgkin's lymphoma; PSC, primary sclerosing cholangitis; PBC, primary biliary cirrhosis; AA, aplastic anemia; RF, rheumatic fever; CGD, chronic granulomatous disease; AS, aortic stenosis; COPD, chronic obstructive pulmonary disease; DM, diabetes mellitus; IVDA intravenous drug abuse; Allo-BM, allogeneic bone marrow; Allo-HSC, allogeneic hematopoietic stem cell; Auto-BM, autologous bone marrow; Auto-HSC, autologous hematopoietic stem cell; MI, myocardial infarction; CF, cystic fibrosis; PR, present report; ND, not described.

^aOnly includes those cases with histology-proven deep tissue invasion by fungal elements and a positive culture for *Scopulariopsis* (*Microascus*) species. Excludes infections of the eye.

^bA disseminated disease type is described as an infection involving multiple organ systems or necrotic lesions involving two or more noncontiguous sites.

^cIncludes anamorphic state (*Scopulariopsis*) or the teleomorphic state (*Microascus*) when recognized.

^dHistory of cardiac surgery.

recognized as causing disease in this patient group, other rare molds such as *Scopulariopsis* (*Microascus*) species have emerged as causes of invasive disease and are causing major issues in the management of these immunocompromised patients [49]. Since 1994, four reviews and two mini-reviews (which represented cardiac cases and

disseminated cases of disease) have described 24 cases involving invasive *Scopulariopsis* (*Microascus*) infections [12,16,18,33–35]. Of these prior cases, 21 met the criteria for invasive infection and inclusion in our evaluation. This report reviews data from 11 additional prior cases and one new case (Case 33) which expands the clinical conditions

Table 2 Methods used to identify proven invasive infection caused by *Scopulariopsis* (*Microascus*) species.

Case No.	Histopathology			Culture identification		Reference
	Inflammatory response	Fungal elements present	Angioinvasive	Method(s)	Species	
1	Non-caseating granuloma	Branched septate hyphae Conidia-like bodies Swollen thick-walled structures Intercalary swollen cells	No	MC	<i>S. brevicaulis</i>	[26]
2	Non-caseating granuloma	Round nonbudding bodies Melanized ^a	No	MC	<i>S. brumptii</i> ^b	[29]
3	ND	Septate hyphae	No	MC	<i>Scopulariopsis</i> species	[8]
4	ND	Uniform septate hyphae Acute angle branching Perpendicular branching	No	MC	<i>Scopulariopsis</i> species	[8]
5	ND	Immature/mature perithecia Ascospores Filaments	No	MC ^c	<i>M. cinereus</i>	[15]
6	ND	Septate hyphae Dichotomous branching	Yes	MC	<i>S. brevicaulis</i>	[25]
7	Granulomatous Necrotic areas	Septate hyphae Dilated cells	No	MC	<i>S. brevicaulis</i>	[23]
8	Bone necrosis	Branching septate hyphae	No	MC	<i>S. candida</i> ^d	[18]
9	Acute granulomatous Necrosis	ND	No	MC	<i>S. brumptii</i>	[21]
10	ND	Branching septate hyphae Moniliform fungal elements	Yes	MC ^c	<i>M. cirrosus</i>	[32]
11	ND	Branching hyphae	No	ND	<i>S. brevicaulis</i>	[11]
12	Granulomatous	Septate hyphae Globose cells Oblong cells in short chains	No	MC ^c	<i>M. cinereus</i>	[24]
13	ND	ND	No	ND	<i>S. brevicaulis</i>	[14]
14	ND	Thin, septate hyphae Branching	Yes	ND	<i>S. acremonium</i> ^b	[16]
15	ND	Septate hyphae Acute angle branching	No	MC ^c	<i>M. cinereus</i>	[9]
16	Granulomatous Necrotic material	Septate hyphae Conidia-like bodies	No	MC	<i>Scopulariopsis</i> species	[17]
17	Dermatic granuloma Microabscess PMN leukocytes	Long hyphae	No	ND	<i>S. brevicaulis</i>	[27]
18	ND	Septate hyphae	No	MC ^c	<i>M. cinereus</i>	[19]
19	Mononuclear cells	Branching septate hyphae	Yes	MC	<i>Scopulariopsis</i> species	[20]
20	ND	Fungal hyphae	No	ND	<i>Scopulariopsis</i> species	[10]
21	ND	Septate true hyphae Vesicular swellings Conidia	Yes	ND	<i>S. brevicaulis</i>	[35]
22	Mixed cell infiltrate	Hyphae Conidia	Yes	MC	<i>S. acremonium</i>	[38]
23	Fungal abscess	Dichotomously branching hyphae Large bulbous protrusions	No	MC ^c D1/D2	<i>M. cirrosus</i>	[30]
24	ND	Septate hyphae	No	ND	<i>S. brevicaulis</i>	[12]
25	Bone necrosis PMN infiltrate	Thin, septate hyphae	Yes	ND	<i>S. acremonium</i> ^b	[31]
26	ND	Branching septate hyphae	No	MC D1/D2	<i>S. brevicaulis</i>	[22]
27	Granulomatous	Hyphae Spores	No	MC Genomic ^e	<i>S. brevicaulis</i>	[28]
28	Sparse inflammation Necrosis	Septate hyphae Branching at acute angles	Yes	ND	<i>Scopulariopsis</i> species	[36]
29	ND	Septate hyphae Branching at acute angles Vesicular swelling of different sizes	No	MC	<i>S. brevicaulis</i>	[34]
30	ND	ND	No	ND	<i>S. brevicaulis</i>	[37]
31	ND	Thin, septate hyphae Fungus ball	No	MC	<i>S. brevicaulis</i>	[13]
32	ND	Septate hyphae	No	MC ^c D1/D2	<i>M. cirrosus</i>	[33]
33	Complete necrosis Mononuclear cells	Septate irregular hyphae Swollen thick-walled structures	Yes	MC ITS2	<i>S. brevicaulis</i>	PR

Abbreviations: MC, micromorphological characteristics; ND, not described; PR, present report; PMN, polymorphonuclear.

^aDescribed as a 'brown pigment' of the fungal element in the tissue.

^bThe micromorphological features of the fungus were neither described nor illustrated.

^cAble to demonstrate mature ascomata (perithecia).

^dThe colonies were described as tan suggesting the possibility of *S. brevicaulis* rather than *S. candida* for which colonies are white.

^eGenomic target not described.

where *Scopulariopsis* infections can occur. Additionally, this report provides a unique focused perspective on the tissue findings and the laboratory methods used to confirm the identification of the *Scopulariopsis* (*Microascus*) species from culture.

Our new case is the first to describe disseminated *Scopulariopsis* infection in a patient with diffuse large B-cell lymphoma who underwent an allogeneic HSCT. The development of multiple dark skin lesions in distant areas in this patient suggested hematologic dissemination from a common focus of primary infection. Fungal blood cultures were done repeatedly on our patient but remained negative. Additionally, no onychomycotic primary source was recognized. The inability to detect this organism in the blood in our case and the low incidence of positive blood cultures for the disseminated cases reviewed (Cases 3, 21, 31, and 32) was not unexpected. This failure to detect mold in blood has been reported with other disseminated infections caused by dry-spored fungi of *Scopulariopsis* or *Aspergillus* [49,50]. In contrast, a high frequency of detection in blood cultures of wet-spored fungi such as *Fusarium*, *Scedosporium*, *Acremonium* and *Trichoderma* has been related to the potential ability of these fungi to sporulate *in vivo* (i.e., adventitious sporulation) [49,51–55]. Importantly, localized invasive skin lesions that were often colored and necrotic were found in several patients with invasive *Scopulariopsis* (*Microascus*) infections [21,32,34–36, present case]. This highlights that skin lesions provide both an index of suspicion for disseminated fungal infection in immunosuppressed patients when other etiologies cannot be identified and a potential source for histopathologic examination and culture.

The histopathological findings from tissue for our new case were similar to those observed with fungi such as the *Aspergillus*, *Fusarium* and *Scedosporium* species, i.e., the presence of hyaline branching septate hyphae. Common findings between our case and other *Scopulariopsis* cases reviewed were the presence of irregularly-shaped hyphae along with swollen thick-walled structures, angioinvasiveness and necrotic tissue formation (Table 2). In 12 cases where conidia, conidia-like bodies, round or swollen structures or ascospores were identified (to include the present reported case), either deep cutaneous, pulmonary, or sinus areas were biopsied, all representing areas where air may be present. Conidia of *S. brevicaulis* are frequently present in nail samples of patients with onychomycosis and are characteristically globose with a flattened base [6]. The swollen structures observed in deep tissues are less likely to be conidial in nature because they lack the typical conidal shape and are smaller in size.

Microascus cinereus, *M. cirrosus*, and *S. brumptii* produce dark-brown pigmented colonies *in vitro* suggesting

that melanin pigment could be used to differentiate these fungi in tissue from *Aspergillus* and other hyaline fungi. However, among the cases reviewed, only one reported brown pigmented hyphae in the tissues (Case 2) [29]. The causative agent in this case was identified as *S. brumptii*. In contrast, there was no report of melanized hyphae in tissue in any of the eight cases caused by *M. cinereus*, *M. cirrosus*, and the other case caused by *S. brumptii*. In a case caused by *M. cirrosus* (Case 10), Krisher *et al.* evaluated tissue using the Fontana-Masson stain but was not able to demonstrate melanin in the tissue [32]. Braddley *et al.*, although not describing pigmented hyphae in tissue in a case of *M. cinereus*-caused disease (Case 18), emphasized the importance of holding cultures of dematiaceous *Scopulariopsis* species for up to 6 weeks to allow for development of ascomata and ascospores because most of the dematiaceous species have been recognized as teleomorphs in the genus *Microascus* [19]. Additionally, the use of special culture media may be required to stimulate ascocarp development. However, even with the use of such conditions, some *Microascus* isolates fail to ascospore as noted by Miossec *et al.* who were able to identify their isolate as *M. cirrosus* by sequencing [33]. Thus, it is possible that isolates identified as *S. brumptii* may be misidentified and in fact represent a teleomorphic species. A further complication is that some species of *Microascus*, such as *M. brevicaulis* (*S. brevicaulis*), *M. manginii* (*S. candida*) and *M. niger* (*S. asperula*), are heterothallic, producing ascomata only when compatible isolates are mated [1,56].

Genomic sequencing of various DNA targets is being used with greater frequency to confirm the species identity of molds [57,58]. Reports have shown that the variable region of the 28S rRNA gene within the rDNA complex can be used as a molecular target to identify *Scopulariopsis* (*Microascus*) species [59–61]. Chung *et al.*, Miossec *et al.*, and Ustun *et al.* all used sequences from this region to identify the species in cases of invasive *Scopulariopsis* infection [22,30,33]. The internal transcribed spacer (ITS) regions (to include both the ITS1 and ITS2 regions) of the rDNA complex has also been shown to be useful for fungal species identification [57,62]. The ITS2 region was found to successfully confirm the identification of *S. brevicaulis* from culture in the new case reported in this study. The greater use of sequencing will allow for clarification of the role of some *Scopulariopsis* species in causing invasive infection, including *S. acremonium*, *S. brumptii* and *S. candida* (see comments Table 2).

In conclusion, this report expands the clinical conditions in which invasive *Scopulariopsis* infections occur and provides an extensive review of the diagnostic methods used to identify cases of invasive *Scopulariopsis* reported

in the literature. Although microscopic analysis of tissue will not distinguish among the various mold pathogens, close observations of distinctive fungal elements especially the presence of conidia or ascospores may provide valuable information in the identification process of *Scopulariopsis* or other molds. Molecular sequencing, although shown to be useful for the identification of fungal species from culture, may also be useful to provide a rapid and accurate identification of the uncommon pathogens such as *Scopulariopsis* directly from tissue.

Acknowledgements

L. Sigler acknowledges grants from the Natural Sciences (#G121210359) and Engineering Council (#G121160004) of Canada.

Declaration of interest: The authors have no conflicts of interest. The authors alone are responsible for the content and writing of the paper.

References

- Abbott SP, Sigler L, Currah RS. *Microascus brevicaulis* sp. nov., the teleomorph of *Scopulariopsis brevicaulis*, supports placement of *Scopulariopsis* with the Microasaceae. *Mycologia* 1998; **90**: 297–302.
- de Hoog G, Guarro, JG, Figueras MJ (eds). *Atlas of Clinical Fungi*, 2nd edn. Utrecht, The Netherlands: Centraalbureau voor Schimmelfcultures, 2000.
- Abbott SP. *Holomorph Studies in the Microasaceae*, 1st edn. Edmonton, AB: University of Alberta, 2000.
- Bonifaz A, Cruz-Aguilar P, Ponce RM. Onychomycosis by molds. Report of 78 cases. *Eur J Dermatol* 2007; **17**: 70–72.
- Issakainen J, Heikkilä H, Vainio E, et al. Occurrence of *Scopulariopsis* and *Scedosporium* in nails and keratinous skin. A five-year retrospective multi-center study. *Med Mycol* 2007; **45**: 201–209.
- Kane J, Summerbell RC, Sigler L, Krajden S, Land G (eds). *Laboratory Handbook of Dermatophytes. A Clinical Guide and Laboratory Manual of Dermatophytes and Other Filamentous Fungi from Skin, Hair, and Nails*, 1st edn. Belmont, CA: Star Publishing Co., 1997.
- Ragge N, Hart J, Easty D, Tyers A. A case of fungal keratitis caused by *Scopulariopsis brevicaulis* treatment with antifungal agent and penetrating keratoplasty. *Br J Ophthalmol* 1990; **74**: 561–562.
- Neglia JP, Hurd DD, Ferrieri P, Snover DC. Invasive *Scopulariopsis* in the immunocompromised host. *Am J Med* 1987; **83**: 1163–1166.
- Celard M, Dannaoui E, Piens MA, et al. Early *Microascus cinereus* endocarditis of a prosthetic valve implanted after *Staphylococcus aureus* endocarditis of the native valve. *Clin Infect Dis* 1999; **29**: 691–692.
- Chen-Scarabelli C, Scarabelli TM. Fungal endocarditis due to *Scopulariopsis*. *Ann Intern Med* 2003; **139**: W77.
- Gentry LO, Nasser MM, Kielhofner M. *Scopulariopsis* endocarditis associated with Duran ring valvuloplasty. *Tex Heart Inst J* 1995; **22**: 81–85.
- Isidro AM, Amorosa V, Stopyra GA, et al. Fungal prosthetic mitral valve endocarditis caused by *Scopulariopsis* species: case report and review of the literature. *J Thorac Cardiovasc Surg* 2006; **131**: 1181–1183.
- Jain D, Oberoi JK, Shahi SK, Shivanani G, Wattal C. *Scopulariopsis brevicaulis* infection of prosthetic valve resembling aspergilloma on histopathology. *Cardiovasc Pathol* 2011; **20**: 381–383.
- Migrino RQ, Hall GS, Longworth DL. Deep tissue infections caused by *Scopulariopsis brevicaulis*: report of a case of prosthetic valve endocarditis and review. *Clin Infect Dis* 1995; **21**: 672–674.
- Aznar C, de Bievre C, Guiguen C. Maxillary sinusitis from *Microascus cinereus* and *Aspergillus repens*. *Mycopathologia* 1989; **105**: 93–97.
- Ellison MD, Hung RT, Harris K, Campbell BH. Report of the first case of invasive fungal sinusitis caused by *Scopulariopsis acremonium*: review of *Scopulariopsis* infections. *Arch Otolaryngol Head Neck Surg* 1998; **124**: 1014–1016.
- Jabor M, Greer D, Amedee R. *Scopulariopsis*: an invasive nasal infection. *Amer J Rhinol* 1998; **12**: 367–371.
- Kriesel JD, Adderson EE, Gooch WM, 3rd, Pavia AT. Invasive sinonasal disease due to *Scopulariopsis candida*: case report and review of scopulariopsis. *Clin Infect Dis* 1994; **19**: 317–319.
- Baddley JW, Moser SA, Sutton DA, Pappas PG. *Microascus cinereus* (anamorph *Scopulariopsis*) brain abscess in a bone marrow transplant recipient. *J Clin Microbiol* 2000; **38**: 395–397.
- Hart AP, Sutton DA, McFeeley PJ, Kornfeld M. Cerebral phaeohyphomycosis caused by a dematiaceous *Scopulariopsis* species. *Clin Neuropathol* 2001; **20**: 224–228.
- Patel R, Gustafiero CA, Krom RA, et al. Phaeohyphomycosis due to *Scopulariopsis brumptii* in a liver transplant recipient. *Clin Infect Dis* 1994; **19**: 198–200.
- Chung W, Sung H, Kim M, et al. Treatment-resistant *Scopulariopsis brevicaulis* infection after filler injection. *Acta Derm Venereol* 2009; **89**: 636–638.
- Creus L, Umbert P, Torres-Rodriguez JM, Lopez-Gil F. Ulcerous granulomatous cheilitis with lymphatic invasion caused by *Scopulariopsis brevicaulis* infection. *J Am Acad Dermatol* 1994; **31**: 881–883.
- Marques A, Kwon-Chung K, Holland S, Turner M, Gallin J. Suppurative cutaneous granulomata caused by *Microascus cinereus* in a patient with chronic granulomatous disease. *Clin Infect Dis* 1995; **20**: 110–114.
- Phillips P, Wood WS, Phillips G, Rinaldi MG. Invasive hyalohyphomycosis caused by *Scopulariopsis brevicaulis* in a patient undergoing allogeneic bone marrow transplant. *Diagn Microbiol Infect Dis* 1989; **12**: 429–432.
- Sekhon AS, Willans DJ, Harvey JH. Deep scopulariopsis: a case report and sensitivity studies. *J Clin Pathol* 1974; **27**: 837–843.
- Sellier P, Monsuez JJ, Lacroix C, et al. Recurrent subcutaneous infection due to *Scopulariopsis brevicaulis* in a liver transplant recipient. *Clin Infect Dis* 2000; **30**: 820–823.
- Wu C, Lee C, HL L, Wu C. Cutaneous granulomatous infection caused by *Scopulariopsis brevicaulis*. *Acta Derm Venereol* 2009; **89**: 103–104.
- Griehle H, Rippon J, Maliwan N, Daun V. *Scopulariopsis* and hypersensitivity pneumonitis in an addict. *Ann Intern Med* 1975; **83**: 326–329.
- Ustun C, Huls G, Stewart M, Marr KA. Resistant *Microascus cirrosus* pneumonia can be treated with a combination of surgery, multiple anti-fungal agents and a growth factor. *Mycopathologia* 2006; **162**: 299–302.
- Beltrame A, Sarmati L, Cudillo L, et al. A fatal case of invasive fungal sinusitis by *Scopulariopsis acremonium* in a bone marrow transplant recipient. *Int J Infect Dis* 2009; **13**: 488–492.
- Krisner K, Holdridge N, Mustafa M, Rinaldi M, McGough D. Disseminated *Microascus cirrosus* infection in pediatric bone marrow transplant recipient. *J Clin Microbiol* 1995; **33**: 735–737.
- Miossec C, Morio F, Lepoivre T, et al. Fatal invasive infection with fungemia due to *Microascus cirrosus* after heart and lung transplantation in a patient with cystic fibrosis. *J Clin Microbiol* 2011; **49**: 2743–2747.
- Salmon A, Debourgogne A, Vasbien M, et al. Disseminated *Scopulariopsis brevicaulis* infection in an allogeneic stem cell recipient:

- case report and review of the literature. *Clin Microbiol Infect* 2010; **16**: 508–512.
- 35 Steinbach WJ, Schell WA, Miller JL, Perfect JR, Martin PL. Fatal *Scopulariopsis brevicaulis* infection in a paediatric stem-cell transplant patient treated with voriconazole and caspofungin and a review of *Scopulariopsis* infections in immunocompromised patients. *J Infect* 2004; **48**: 112–116.
- 36 Swick BL, Reddy SC, Friedrichs A, Stone MS. Disseminated *Scopulariopsis*-culture is required to distinguish from other disseminated mould infections. *J Cutan Pathol* 2010; **37**: 687–691.
- 37 Szentel J, Kam J, Yohendran J, Morrissey O, Hall A. Presumed *Scopulariopsis brevicaulis* chorioretinitis in a stem cell transplant recipient. *Clin Exp Ophthalmol* 2010; **38**: 314–315.
- 38 Wuyts WA, Molzahn H, Maertens J, et al. Fatal *Scopulariopsis* infection in a lung transplant recipient: a case report. *J Heart Lung Transplant* 2005; **24**: 2301–2304.
- 39 De Pauw B, Walsh TJ, Donnelly JP, et al. Revised definitions of invasive fungal disease from the European Organization for Research and Treatment of Cancer/Invasive Fungal Infections Cooperative Group and the National Institute of Allergy and Infectious Diseases Mycoses Study Group (EORTC/MSG) Consensus Group. *Clin Infect Dis* 2008; **46**: 1813–1821.
- 40 Iwen PC, Sigler L, Noel RK, Freifeld AG. *Mucor circinelloides* was identified by molecular methods as a cause of primary cutaneous zygomycosis. *J Clin Microbiol* 2007; **45**: 636–640.
- 41 White T, Burns T, Lee S, Taylor J (eds). *PCR Protocols. A Guide to Methods and Applications*, 1st edn. San Diego, CA: Academic Press, Inc., 1990.
- 42 Mohammadi I, Piens MA, Audigier-Valette C, et al. Fatal *Microascus trigonosporus* (anamorph *Scopulariopsis*) pneumonia in a bone marrow transplant recipient. *Eur J Clin Microbiol Infect Dis* 2004; **23**: 215–217.
- 43 Satyavani M, Viswanathan R, Harun N, Mathew L. Pulmonary *Scopulariopsis* in a chronic tobacco smoker. *Singapore Med J* 2010; **51**: e137–139.
- 44 Vignon M, Michonneau D, Baixench MT, et al. Disseminated *Scopulariopsis brevicaulis* infection in an allogeneic stem cell recipient. *Bone Marrow Transplant* 2011; **46**: 1276–1277.
- 45 Wagner E, Sander A, Bertz H, Finke J, Kern W. Breakthrough invasive infection due to *Debaryomyces hansenii* (teleomorph *Candida famata*) and *Scopulariopsis brevicaulis* in a stem cell transplant patient receiving liposomal amphotericin B and caspofungin for suspected aspergillosis. *Infection* 2005; **33**: 397–400.
- 46 Wheat LJ, Bartlett M, Ciccarelli M, Smith JW. Opportunistic *Scopulariopsis* pneumonia in an immunocompromised host. *South Med J* 1984; **77**: 1608–1609.
- 47 Shankar EM, Vignesh R, Barton RC, et al. Hydrothorax in association with *Scopulariopsis brumptii* in an AIDS patient in Chennai, India. *Trans R Soc Trop Med Hyg* 2007; **101**: 1270–1272.
- 48 Lai CC, Tan CK, Huang YT, Shao PL, Hsueh PR. Current challenges in the management of invasive fungal infections. *J Infect Chemother* 2008; **14**: 77–85.
- 49 Walsh TJ, Groll A, Hiemenz J, et al. Infections due to emerging and uncommon medically important fungal pathogens. *Clin Microbiol Infect* 2004; **10** (Suppl. 1): 48–66.
- 50 Klingspor L, Loeffler J. *Aspergillus* PCR formidable challenges and progress. *Med Mycol* 2009; **47** (Suppl. 1): S241–S247.
- 51 Schell WA. New aspects of emerging fungal pathogens. A multifaceted challenge. *Clin Lab Med* 1995; **15**: 365–387.
- 52 Schell WA, Perfect JR. Fatal, disseminated *Acremonium strictum* infection in a neutropenic host. *J Clin Microbiol* 1996; **34**: 1333–1336.
- 53 Lin K, Howell DN, Perfect JR, Schell WA. Morphologic criteria for the preliminary identification of *Fusarium*, *Paecilomyces*, and *Acremonium* species by histopathology. *Am J Clin Pathol* 1998; **109**: 45–54.
- 54 Cortez K, Roilides E, Quiroz-Telles F, et al. Infections caused by *Scedosporium* spp. *Clin Microbiol Rev* 2008; **21**: 157–197.
- 55 Nucci M, Anaissie E. *Fusarium* infections in immunocompromised patients. *Clin Microbiol Rev* 2007; **20**: 695–704.
- 56 Abbott SP, Lumley TC, Sigler L. Use of holomorph characters to delimit *Microascus nidicola* and *M. soppii* sp. nov., with notes on the genus *Pithoascus*. *Mycologia* 2002; **94**: 362–369.
- 57 Balajee SA, Sigler L, Brandt ME. DNA and the classical way: identification of medically important molds in the 21st century. *Med Mycol* 2007; **45**: 475–490.
- 58 Borman AM, Linton CJ, Miles SJ, Johnson EM. Molecular identification of pathogenic fungi. *J Antimicrob Chemother* 2008; **61** (Suppl. 1): i7–12.
- 59 Issakainen J, Jalava J, Hyvönen J, et al. Relationships of *Scopulariopsis* based on LSU rDNA sequences. *Med Mycol* 2003; **41**: 31–42.
- 60 Ebihara M, Makimura K, Sato K, Abe S, Tsuboi R. Molecular detection of dermatophytes and nondermatophytes in onychomycosis by nested polymerase chain reaction based on 28S ribosomal RNA gene sequences. *Br J Dermatol* 2009; **161**: 1038–1044.
- 61 Vollmer T, Stormer M, Kleesiek K, Dreier J. Evaluation of novel broad-range real-time PCR assay for rapid detection of human pathogenic fungi in various clinical specimens. *J Clin Microbiol* 2008; **46**: 1919–1926.
- 62 Iwen PC, Hinrichs SH, Rupp ME. Utilization of the internal transcribed spacer regions as molecular targets to detect and identify human fungal pathogens. *Med Mycol* 2002; **40**: 87–109.

This paper was first published online on Early Online on 20 April 2012.