

Medical Management of *Beauveria bassiana* Keratitis

Timothy A. Kisla, D.O., Andrew Cu-Unjieng, M.D., Lynne Sigler, M.S., and
Joel Sugar, M.D.

Purpose. To describe a case of *Beauveria bassiana* keratitis and to discuss the management of this rare condition. **Methods.** An 82-year-old woman underwent surgical repair of a graft wound dehiscence. Seven months later, shortly after the removal of sutures, the patient developed a fungal keratitis. *B. bassiana* was identified as the infecting organism. The patient was treated with topical natamycin and oral fluconazole. **Results.** Following antifungal therapy, the corneal ulcer was eradicated, but the patient underwent repeat penetrating keratoplasty for decreased vision due to corneal edema. The graft remains clear and visual acuity is substantially improved. **Conclusion.** The medical management of *B. bassiana* keratitis has previously been unsuccessful. The use of topical natamycin combined with oral fluconazole in the management of this case is discussed.

Key Words: Fungal keratitis—*Beauveria*—Natamycin.

B. bassiana is a common soil fungus with a worldwide distribution.¹ It is best known as a pathogen of silkworms and many other insects. It rarely causes human infection, especially involving the eye.² Two cases of *B. bassiana* keratitis have been reported previously.^{3,4} Both required penetrating keratoplasty for resolution of the infection. We report a case of *B. bassiana* keratitis treated successfully with topical natamycin and oral fluconazole.

CASE REPORT

An 82-year-old woman underwent surgical repair of inferior graft wound dehiscence and anterior vitrectomy on her right eye following blunt trauma in June, 1997. This eye previously underwent penetrating keratoplasty, extracapsular cataract extraction, and placement of a posterior chamber intraocular lens in January, 1989 for Fuchs' corneal endothelial dystrophy and cataract. The patient was examined and sutures were removed in December, 1997. One month later, the patient complained of decreased vision,

a foreign body sensation, and mild aching in her right eye. Examination revealed a visual acuity of 20/200 and a sectoral area of edema within the graft. The patient was treated with topical prednisolone acetate. When seen six days later, the patient complained of a further decrease in vision, photophobia, tearing, and pain in her right eye. Visual acuity had decreased to perception of hand motions with direction. The corneal graft was diffusely edematous with an inferior epithelial defect but with no infiltrate. The prednisolone acetate was discontinued and gentamicin ointment was administered every two hours. Six days later, the patient's symptoms persisted. The right eye was profoundly injected with increased corneal edema and a substantial anterior chamber inflammatory response. A stromal infiltrate was noted in the area of the epithelial defect (Fig. 1).

Smears stained with Giemsa revealed the presence of polymorphonuclear leukocytes and septate hyphae. Media were inoculated for cultures of bacteria and fungi including blood, chocolate, brain–heart infusion agars, and eugonic broth for anaerobes. Bacterial cultures yielded no growth while fungal cultures grew 14 colonies of a white mold identified provisionally as *Beauveria* species. With evidence of a fungal infection, therapy with gentamicin was discontinued and the patient was given natamycin 5% suspension every hour and 200 mg oral fluconazole every twelve hours. Subsequently, the fungus was referred to the University of Alberta Microfungus Collection and Herbarium where it was deposited as UAMH 9213. The fungus was identified as *B. bassiana* by its colonial and microscopic features.² Colonies on potato dextrose agar (Difco Laboratories, Detroit, MI, U.S.A.) were yellowish white, moderately fast growing, dense, and from powdery to woolly in texture. The conidia (asexual spores) were produced from small pegs formed in a zig-zag arrangement at the tips of the conidiogenous cells (spore bearing cells) that are swollen at the base (Fig. 2).

The oral fluconazole was discontinued after three weeks. The topical natamycin was tapered to four times daily and the infiltrate progressively improved as the epithelial defect became smaller. The patient's visual acuity remained at only counting fingers from a distance of 1 ft because of persistent corneal edema. In April, 1998, the patient underwent a repeat penetrating keratoplasty. Histopathologic examination of the excised tissue revealed the presence of corneal stromal thinning, edema, vascularization, and scarring. Gomori's methenamine silver and Brown & Hopps stains were negative for fungal elements. Eleven months after penetrating keratoplasty, the patient's postoperative course was uneventful. The corneal graft was clear and uncorrected acuity was 20/60 with macular degenerative changes present.

Submitted July 7, 1999. Revision received October 17, 1999. Accepted October 23, 1999.

From the University of Illinois at Chicago Eye Center (T.A.K., A.C.-U., J.S.), Department of Ophthalmology and Visual Sciences, Chicago, Illinois, U.S.A.; and the University of Alberta Microfungus Collection and Herbarium (L.S.), Devonian Botanic Garden and Medical Microbiology and Immunology, Edmonton, Alberta, Canada.

Please address correspondence and reprint requests to Dr. Joel Sugar, 1855 West Taylor Street, Chicago, Illinois 60612, U.S.A.

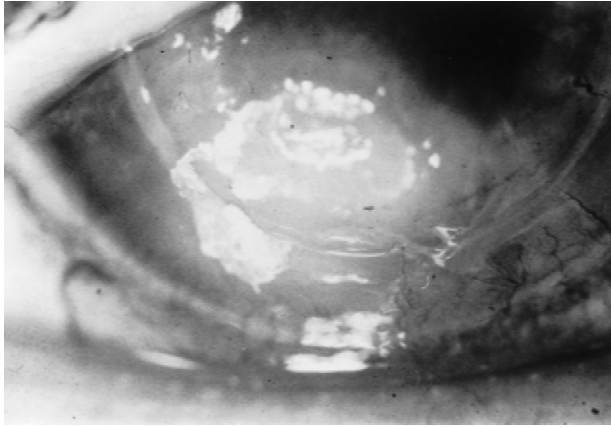


FIG. 1. Patient's cornea with epithelial defect and fungal infiltrate.

DISCUSSION

Thomas⁵ has reported that more than 70 species belonging to 40 genera have been identified as agents of mycotic keratitis. Species of *Beauveria* have rarely been found to cause ocular disease. Three cases, including the present one, concern *B. bassiana*, by far the most common species on insects and in soil and many other substrates. A single report identified *B. alba* (also known as *Engyodontium album*) as the causative organism.⁶ Microscopically these species differ in the form of their conidiogenous cells, which are formed in whorls or in aggregations and are basally swollen in *B. bassiana* and are solitary and non-swollen in *B. alba*.² Sachs et al.³ referred to another report of mycotic keratitis concerning *B. brumpti*, but that species was later identified as a synonym of *Tritirachium oryzae*, a fungus with somewhat similar conidiogenesis also known as a rare cause of keratitis.⁷

Appropriate medical management of *B. bassiana* keratitis is not yet known. In 1985, Sachs et al.³ reported the first case of *B. bassiana* keratitis in a patient following the removal of a corneal

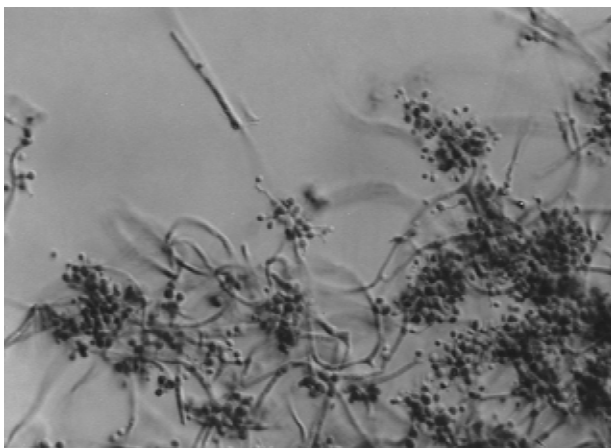


FIG. 2. Microscopic appearance of *B. bassiana* showing conidiogenous cells with zig-zag tips formed in typical dense clusters along hyphae. Slide culture preparation, original magnification $\times 580$.

foreign body; medical therapy consisted of a chloramphenicol-polymyxin-hydrocortisone ointment in addition to atropine drops. In 1997, Low et al. (4) described a patient who had a caterpillar hair embedded in her cornea and who was treated with a combination of miconazole 1% and natamycin 5%. In both cases, therapy failed to halt the progression of the corneal disease and surgery, in the form of either penetrating keratoplasty³ or deep lamellar dissection,⁴ was necessary to effect cure.

Oral fluconazole, when added to topical natamycin, has been reported as an effective treatment in a case of filamentous fungal keratitis.⁸ This combination proved effective in our patient who was treated with fluconazole for three weeks and topical natamycin for three months. In this case, antifungal therapy reduced ocular inflammation and eliminated the mycotic infection. Our patient's cornea was free of fungal elements at the time of keratoplasty, which was done because of poor vision. The success of penetrating keratoplasty in keratomycosis is enhanced when ocular inflammation is reduced to some extent prior to the procedure.^{9,10} Most cases of fungal keratitis follow trauma to the eye, as occurred with our patient. Other circumstances may have contributed to the onset of infection. Tseng et al.¹¹ identified several precipitating factors associated with late microbial keratitis, which included epithelial defects, suture related problems, use of contact lenses, trichiasis, dry eye, and lid abnormalities. Our patient was noted to have an epithelial defect prior to the observation of the stromal infiltrate. The patient was also treated with topical corticosteroids and antibiotics prior to the identification of mycotic elements and the initiation of antifungal therapy. This therapy may have depressed the normal protective mechanisms, promoted fungal invasion, and aggravated the patient's course. The use of topical and systemic antifungal therapy in this patient appeared to eliminate her fungal infection as no fungal elements were retrievable from her keratoplasty specimen and her outcome was very good.

REFERENCES

1. Domsch KH, Gams W, Anderson T. *Compendium of soil fungi*. New York: Academic Press, 1980. (Reprinted Eching, Germany: IHW-Verlag, 1993.)
2. Sigler L, Kennedy MJ. Aspergillus, Fusarium and other opportunistic moniliaceous fungi. In: Murray PR, Baron EJ, Pfaller MF, Tenover FC, Tenover RH, eds. *Manual of clinical microbiology*. Washington D.C.: American Society for Microbiology, 1999:1212-41.
3. Sachs SW, Baum J, Mies C. *Beauveria bassiana* keratitis. *Br J Ophthalmol* 1985;69:548-50.
4. Low CAT, Badenoch PR, Coster DJ. *Beauveria bassiana* keratitis cured by deep lamellar dissection. *Cornea* 1997;16:698-9.
5. Thomas PA. Mycotic keratitis: an underestimated mycosis. *J Med Vet Mycol* 32:235-56.
6. McDonnell PJ, Werblin TP, Sigler L, Green WR. Mycotic keratitis due to *Beauveria alba*. *Cornea* 1984/1985;3:213-6.
7. DeHoog GS, Guarro J. *Atlas of clinical fungi*. Baarn, Netherlands: Centraalbureau voor Schimmelcultures, 1985.
8. Thakar M. Oral fluconazole therapy for keratomycosis. *Acta Ophthalmologica* 1994;72:765-7.
9. Polack FM, Kaufman HE, Newmark E. Keratomycosis. *Arch Ophthalmol* 1971;85:410-6.
10. O'Day DM, Moore TE, Aronson SB. Deep fungal corneal abscess. *Arch Ophthalmol* 1971;86:414-9.
11. Tseng S-H, Ling K-C. Late microbial keratitis after corneal transplantation. *Cornea* 1995;14:591-4.