

Mycetoma of the Foot Caused by *Cylindrocarpon destructans*

D. E. ZOUTMAN^{1†} AND L. SIGLER^{1,2*}

Department of Medical Microbiology and Infectious Diseases,¹ and the Microfungus Collection and Herbarium,² University of Alberta, Edmonton, Alberta, Canada T6G 2E1

Received 8 April 1991/Accepted 14 June 1991

A 39-year-old male, originally from Antigua, West Indies, presented with a 12-year history of swelling of the left foot. A pathogen could not be recovered in cultures of three surgical biopsy specimens. During follow-up, pus and grains were expressed from a draining sinus tract and *Cylindrocarpon destructans* grew in pure culture. Retrospective examination of histologic sections of tissue removed during the third biopsy demonstrated a grain characteristic of eumycotic mycetoma. Although the fungus was susceptible to amphotericin B and ketoconazole in vitro, the patient refused treatment, and the clinical course over almost 19 years has been one of slow but progressive bone destruction. The fungus was identified by its microconidial morphology, the presence of chlamydospores, and an intense brown diffusible pigment. It was compared with another poorly known agent of white grain mycetoma, *Phialophora cyanescens*, characterized by phialidic conidia, chlamydospores in aggregations, and an intense diffusing pigment. The new combination *Cylindrocarpon cyanescens* (de Vries et al.) Sigler comb. nov. is proposed.

Like species of the genus *Fusarium*, members of the genus *Cylindrocarpon* are cosmopolitan soil fungi often associated with plant roots (1, 2, 6). They may be saprobes or facultative plant pathogens. *Cylindrocarpon* spp. are similar to *Fusarium* spp. in that they have teleomorphs in the genus *Nectria* (where known) and they produce slimy, multicelled conidia (macroconidia) often accompanied by single-celled microconidia and chlamydospores. Macroconidia lack the distinctive foot cell characteristic of *Fusarium* spp. Although some species of *Fusarium* are increasingly being recognized as agents of infection, especially in immunocompromised hosts (17, 20), reports of infections caused by *Cylindrocarpon* spp. are rare. *Cylindrocarpon lichenicola* (originally reported under the name *C. tonkinense*) and *C. vaginae* have been reported to cause keratitis (3, 4, 10, 11), but we are not aware of any previous reports of *C. destructans* having been isolated from human infection. This report describes a case of white grain mycetoma of the foot caused by *C. destructans*.

MATERIALS AND METHODS

Case report. A 39-year-old male, originating from Antigua, West Indies, presented in 1984 with a 12-year history of a swelling on the lateral aspect of his left foot which intermittently drained pus. In 1972, at the age of 24 years, he suffered a deep nail puncture to the sole of his left foot while building a house with pine lumber. His foot became swollen and painful for several weeks, and the patient noted purulent yellow drainage which contained granular material. The swelling, pain, and drainage subsided, and he was able to walk normally and without pain. However, from that time on, the left foot intermittently drained yellow purulent material from a chronically draining sinus tract. He did not seek medical treatment at that time. Three years later he emigrated to Canada, and in 1983, he saw an orthopedic surgeon who made the diagnosis of osteomyelitis on the

basis of the clinical appearance and the results of roentgenograms and a technetium bone scan of the foot. Examination of the foot was unremarkable except for a single draining sinus 3 cm anterior to the lateral malleolus. The roentgenograms of the left foot demonstrated lytic destruction of the lateral calcaneus, navicular, and cuboid bones (Fig. 1a). The bone scan showed increased uptake in the lytic areas (Fig. 1b). During a surgical open biopsy of the lateral forefoot in 1983, purulent material was removed from the metatarsals, and curettings from the affected areas of bone were obtained. These specimens were submitted for bacterial and fungal cultures. Histologic examination revealed changes of chronic inflammation only. Because no pathogens grew from these cultures, two additional biopsies were done. However, neither surgical specimen grew any pathogens on bacteriologic or mycologic media. It was only upon a third biopsy in 1984 that a white grain characteristic of a eumycotic mycetoma was seen in the histologic sections of the bone tissue (Fig. 2 and 3). For the ensuing 3 years after the third biopsy, the patient declined any systemic antifungal therapy and continued to be employed as an office clerk, although he still had occasional drainage from the sinus tract.

During a follow-up visit in the fall of 1987, the patient was able to express pus from the sinus tract while in the clinic. After careful surface cleaning of the sinus tract and the adjacent area with alcohol, additional pus was expressed onto the surface of a sterile cotton-tipped swab. Several small (diameter, 0.5-mm) white grains were noted. The material was immediately plated onto solid medium in the clinic. Follow-up roentgenograms demonstrated slow progression of the infection into the talus and the tarsals of the left foot. Since 1987, the patient has declined to be admitted into a hospital for intravenous amphotericin B therapy or to take oral ketoconazole. Despite the lack of therapy and radiologic extension of the infection, he remains mobile and almost painfree.

Isolation and identification of the fungus. The entire original specimen, consisting of grains and pus, was plated directly onto phytone yeast extract agar (PYE) and brain heart infusion agar (BHI) (both from BBL Microbiology Systems, Cockeysville, Md.) and onto tryptic soy agar with 5% sheep blood. PYE and BHI plates were incubated at

* Corresponding author.

† Present address: Department of Medical Microbiology, Kingston General Hospital, Queen's University, Kingston, Ontario, Canada K7L 3N6.

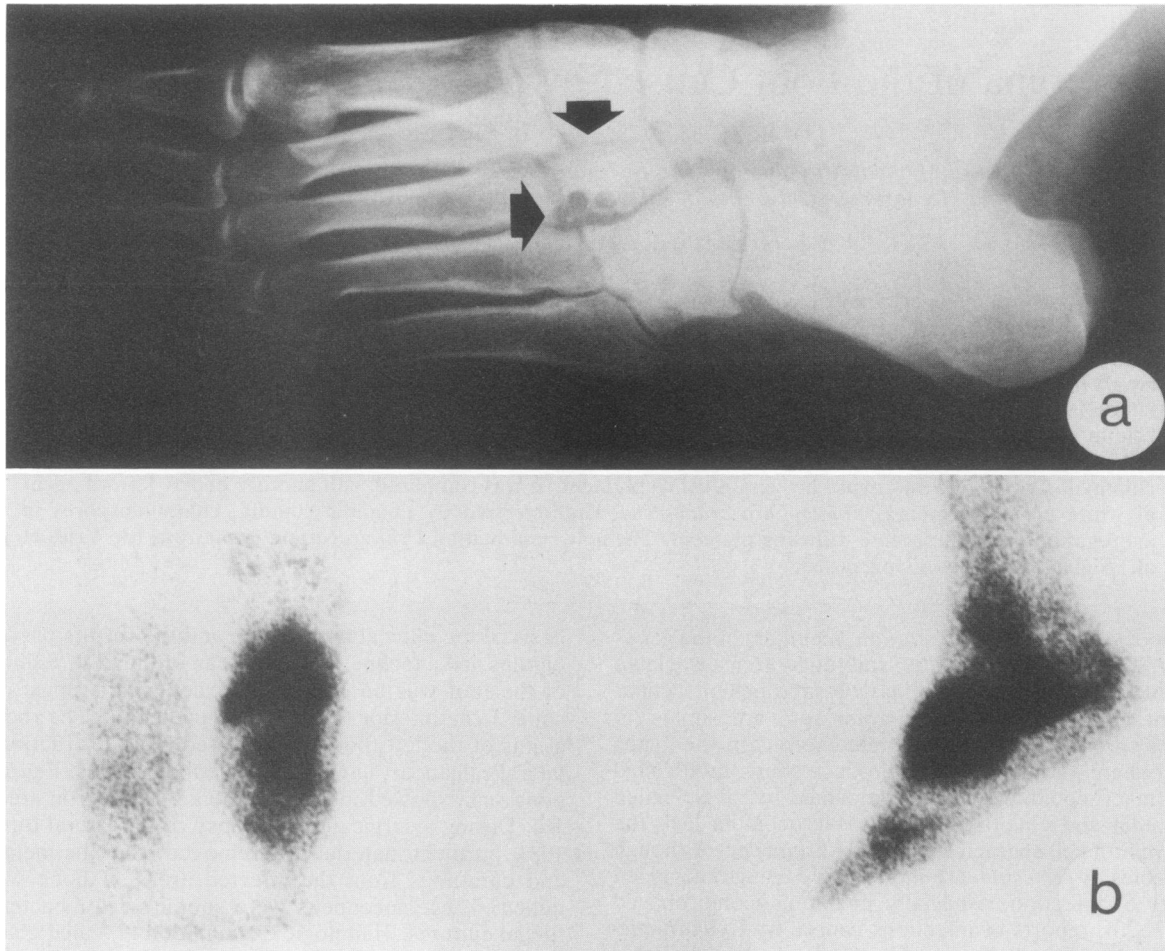


FIG. 1. (a) Roentgenogram of the left foot demonstrating lytic bone destruction of the tarsals and the base of the third metatarsal (arrows). (b) Technetium-99m bone scan of the left foot taken 3 h after injection of technetium-99m demonstrating uptake of the technetium throughout the foot. The scan in panel b was taken at the same time as the roentgenogram shown in panel a (1984).

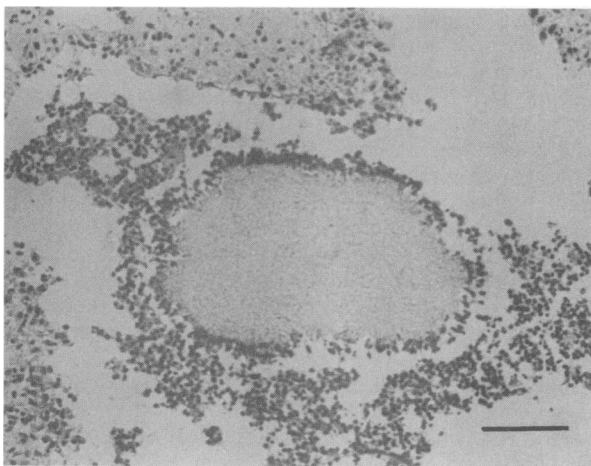


FIG. 2. White grain of *C. destructans*; hematoxylin and eosin stain. Magnification, $\times 120$. Bar, $100 \mu\text{m}$.

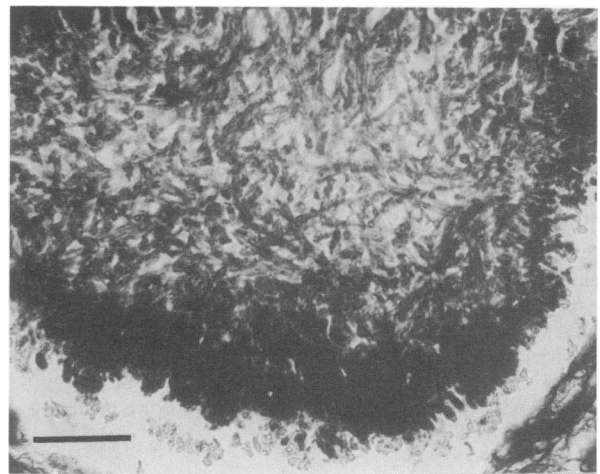


FIG. 3. White grain of *C. destructans* showing a loose network of hyphae; Gomori methenamine-silver stain. Magnification, $\times 313$. Bar, $40 \mu\text{m}$.

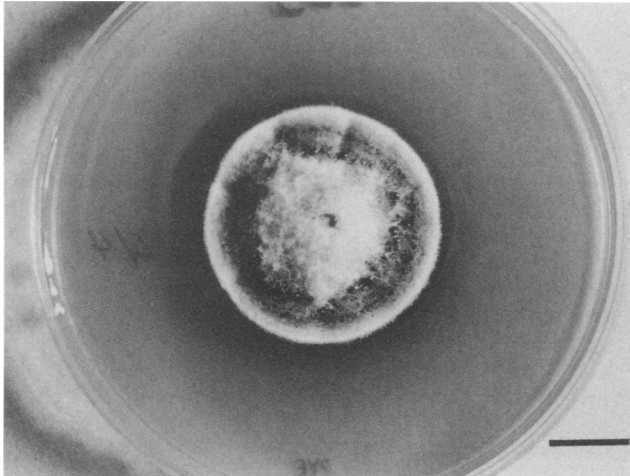


FIG. 4. Colony of *C. destructans* UAMH 5863 on PYE after 3 weeks at 25°C. Magnification, $\times 0.8$. Bar, 1.0 cm.

25°C, and tryptic soy agar with 5% sheep blood and a second BHI plate were incubated at 35°C.

Observations of colonial morphology were made on potato dextrose agar (PDA) (Difco Laboratories, Detroit, Mich.) and PYE. The media used to enhance sporulation included PDA, pablum cereal agar (14), and carnation leaf agar (13). Color terms were determined by using the color standards of Kornerup and Wanscher (9).

Antifungal susceptibility testing. In vitro antifungal susceptibility testing was performed at the Fungus Testing Laboratory, The University of Texas Health Science Center at San Antonio, San Antonio, Tex., by a broth macrodilution method in synthetic amino acid medium-fungal at 25°C by using an inoculum of 10^{-4} cells (12, 16). The antifungal agents tested included amphotericin B, 5-flucytosine, miconazole, and ketoconazole.

RESULTS

Primary isolation. After 10 days of incubation at 25°C, the BHI and PYE plates yielded 10 to 15 5-mm-diameter colonies of a raised cottony red-brown fungus, particularly at those areas where the grains were embedded into the agar. The growth was somewhat slower at 35°C, but the colonial morphologies were similar at both temperatures. No other organisms were grown from the specimen.

Description of the pathogen. On PDA and PYE plates, colonies were slow growing, attaining diameters of 28 and 40 mm, respectively, after 21 days of growth at 25°C. On PYE (Fig. 4), aerial growth was profuse, cottony, raised 4 to 5 mm in height, reddish brown (color term from color plate 9E7 [9]) toward the periphery, and dull red (8C4) in the center, with pale orange exudate droplets on the surface. The margin was pale grey. A brownish orange to light brown pigment (7C/D8) diffused into the medium, and by 5 weeks, the medium had turned dark brown (8F8). Colonies on PDA plates were flatter and were reddish brown (8E6) with a light brown diffusing pigment (7D7). At 35°C, growth on PDA plates was slower (20 to 22 mm in diameter in 21 days), and colonies were brownish orange with a light brown to brownish orange diffusing pigment.

The conidiogenous cells were *Acremonium* spp.-like orthophialides (8), being solitary or having one or two basal

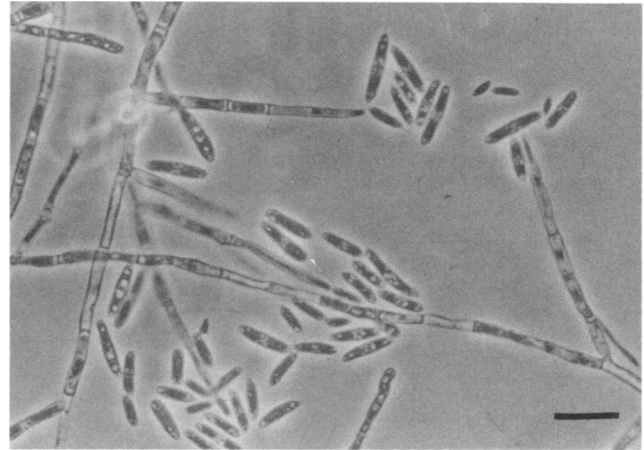


FIG. 5. Septate phialides and zero to one septate microconidia of *C. destructans*. Magnification, $\times 420$. Bar, 20 μm .

branches. However, the phialides of *C. destructans* differed from most *Acremonium* species in that they were slightly broader. They were slender; cylindrical to subulate; subtended by one or more basal septa, with the terminal cell measuring 27 to 32 by 2.5 to 3 μm ; and tapering at the apex to 2 to 2.5 μm to form a nonflared collarette (Fig. 5 and 6). Macroconidia were rare in all cultures, but a few two- or three-septate conidia measuring 23 to 28 by 4 to 5 μm were observed in slide culture preparations by using pablum cereal agar as the medium. These were straight or slightly curved, cylindrical, and tapered at the base. Microconidia also were not abundant and measured 7 to 14 by 3 to 4.5 μm when they were nonseptate and 11 to 24 by 4 to 5 μm when they were one-septate. They were oval to elliptical, sometimes slightly curved, and formed in slimy masses (Fig. 5). Chlamydospores were solitary or in short chains; intercalary or terminal; at first hyaline and smooth, becoming pale brown and warty, globose, or broadly pyriform; and measuring 8 to 11 by 7 to 10 μm (Fig. 7). The isolate was deposited in the University of Alberta Microfungus Collection and Herbarium as strain UAMH 5863 and in the University of Texas Health Science Center as strain UTHSC R-699. It was identified as *C. destructans* by G. J. Samuels

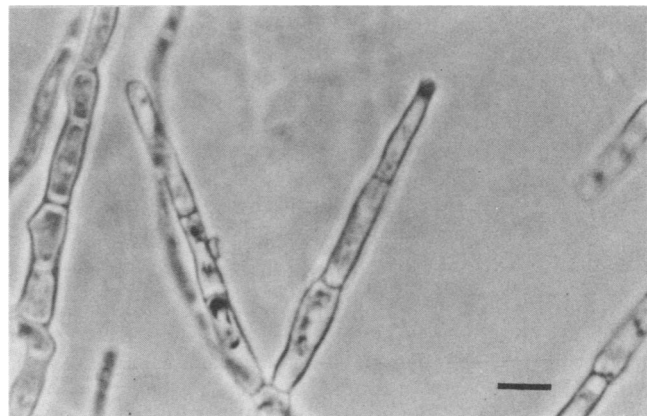


FIG. 6. Nonflared collarette of phialide, *C. destructans*. Magnification, $\times 900$. Bar, 10 μm .

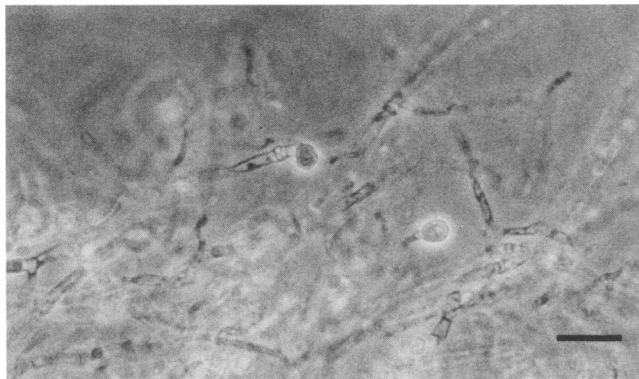


FIG. 7. Solitary chlamydospores of *C. destructans*. Magnification, $\times 420$. Bar, 20 μm .

(18) on the basis of microconidial morphology, the presence of chlamydospores, and intense brown soluble pigment.

In vitro antimycotic susceptibility tests read at 24 h showed that our isolate was susceptible to amphotericin B (MIC, 1.16 $\mu\text{g/ml}$; minimum lethal concentration, 2.31 $\mu\text{g/ml}$) and ketoconazole (MIC, 3.2 $\mu\text{g/ml}$; minimum lethal concentration, 12.8 $\mu\text{g/ml}$) but was resistant to 5-flucytosine (MIC, >322.75 $\mu\text{g/ml}$) and miconazole (MIC, >20 $\mu\text{g/ml}$).

DISCUSSION

Most cases of mycetoma occur in tropical or subtropical areas. *C. destructans*, which is known as both a root pathogen and as a saprobe in soil, has a wide distribution in temperate areas, but it is less commonly reported in the tropics and subtropics (2, 6). The teleomorph (*Nectria radicolica*) has been found in tropical America (18). *C. destructans* has not been reported previously as an etiologic agent of mycetoma, but many of the fungal agents of mycetoma are soil saprobes or plant pathogens which only incidentally infect humans, often following trauma. The method of inoculation in the patient described here was undoubtedly the deep puncture wound sustained in 1972. The initial infection was quite acute but subsided and has followed a chronic course characteristic of mycetomas caused by other agents. Although it seems remarkable that the fungus was not grown from any of the first three biopsy specimens, the first two biopsies could have obtained samples from the wrong area, because the histology showed evidence only of chronic inflammation without fungal elements. However, histology of the third biopsy specimen revealed a typical white eumycotic grain which established mycetoma as the pathologic process. Our observation of grains expelled in purulent material from a sinus tract and the isolation of multiple colonies of *C. destructans* in culture are convincing evidence that the fungus isolated represented the pathogen in this case. Furthermore, the presence of grains, swelling, and bone destruction fit the clinical picture of eumycotic mycetoma.

Although this *C. destructans* isolate was susceptible to ketoconazole and amphotericin B in vitro, clinical studies which support the use of these agents in the treatment of mycetoma are few in number and anecdotal in nature (7, 15). No randomized trials of the management of mycetoma have ever been reported. Some feel that surgery is an important approach early on to remove as much of the infected tissue as possible while still attempting to preserve limb function

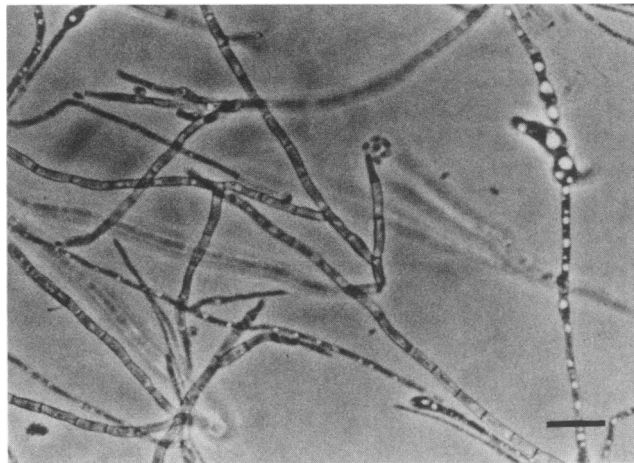


FIG. 8. *C. cyanescens* UAMH 5865. Septate phialides, oval conidia, and early development of chlamydospores are shown. Magnification, $\times 420$. Bar, 20 μm .

(21). In the case presented here, neither approach was acceptable to the patient, and he has maintained the function of his foot for over 19 years.

Our isolate appeared to be unusual for *C. destructans* in its paucity of conidia, but this degeneration may have been a result of its adaptation to growth in human tissue. After several subcultures, sectors of more rapid growth developed in some cultures, but even these sectors failed to demonstrate macroconidia of the size reported for typical isolates. These can measure (25-) 29.4 to 36.3 (-46) μm in length and (4-) 5 to 7.5 (-8) μm in width (19). Macroconidia are commonly three-septate when the fungus is growing in culture, but they are more variable on the host and may be one- to seven-septate (19).

Another slow-growing, poorly sporulating agent of white grain mycetoma distinguished by the production of chlamydosporelike aggregations and brown or blue diffusing pigment was described as *Phialophora cyanescens* (5). Examination of the ex-type strain (culture derived from the type specimen; CBS 518.82 = UAMH 5865) revealed cylindrical phialides with nonflaring collarettes (Fig. 8) that produced small oval conidia measuring 4 to 7.5 by 2 to 3 μm and chains of swollen chlamydospores, which may aggregate into clusters (Fig. 9). Although it can be distinguished from *C. destructans* by its extremely slow growth (2 to 3 mm after 15 days at 20 to 22°C), small conidia, the lack of multicelled conidia, and aggregates of chlamydospores, *P. cyanescens* is more similar to species of *Cylindrocarpon* than it is to other *Phialophora* species, which are usually darkly pigmented and often have distinctive collarettes. Its failure to produce macroconidia appears to preclude its accommodation in members of the genus *Cylindrocarpon*, but the situation is analogous to that of the genus *Fusarium*, in which species such as *F. moniliforme* (a later synonym of *F. verticillioides*), in which macroconidia have not been described from the type specimen, or *F. proliferans*, in which macroconidia are rarely produced in culture, are recognized as belonging to *Fusarium* species on the basis of their microconidial states (20). Therefore, the following combination is proposed: *Cylindrocarpon cyanescens* (de Vries, de Hoog & de Bruyn) Sigler comb. nov. (basonym: *Phialophora cyanescens* de Vries, de Hoog & de Bruyn; Antonie van Leeuwenhoek 50: 150, 1984).

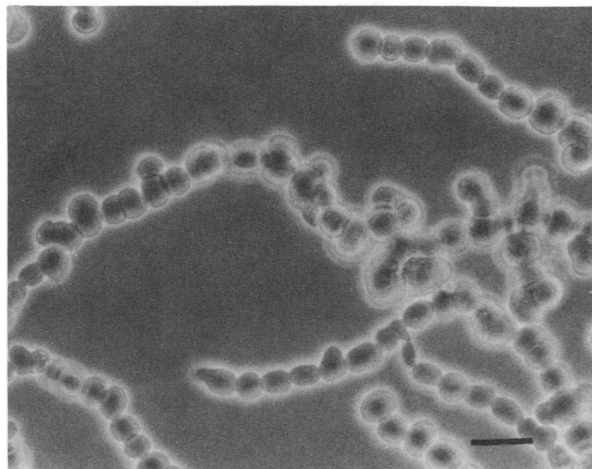


FIG. 9. *C. cyanescens* UAMH 5865. Chlamydospores in chains and aggregates are shown. Magnification, $\times 420$. Bar, 20 μm .

ACKNOWLEDGMENTS

The assistance of G. J. Samuels in confirming the identity of the fungus and of M. G. Rinaldi in performing the antifungal susceptibility tests is gratefully acknowledged. Expert technical assistance from A. Flis and the cooperation of the Centraalbureau voor Schimmelcultures, Baarn, The Netherlands, in provision of the ex-type of *P. cyanescens* is acknowledged.

L.S. is the recipient of a grant from the Natural Sciences and Engineering Research Council of Canada (OGP 3755), and D.E.Z. is the recipient of a grant from the Alberta Heritage Foundation for Medical Research.

REFERENCES

- Booth, C. 1966. The genus *Cylindrocarpon*. CAB Int. Mycol. Inst. Mycol. Papers **104**:1–56.
- Booth, C. 1967. *Nectria radicolica*. CMI descriptions of pathogenic fungi and bacteria no. 148. Commonwealth Mycological Institute, Kew, United Kingdom.
- Booth, C., Y. M. Clayton, and M. Usherwood. 1985. *Cylindrocarpon* species associated with mycotic keratitis. Proc. Indian Acad. Sci. Plant Sci. **94**:433–436.
- Brayford, D. 1987. *Cylindrocarpon lichenicola*. CMI descriptions of pathogenic fungi and bacteria no. 926. Mycopathologia **100**:125–126.
- De Vries, G. A., G. S. de Hoog, and H. P. de Bruyn. 1984. *Phialophora cyanescens* sp. nov. with *Phaeosclera*-like synanamorph causing white grain mycetoma in man. Antonie van Leeuwenhoek J. Microbiol. **50**:149–153.
- Domsch, K. H., W. Gams, and T.-H. Anderson. 1980. Compendium of soil fungi. Academic Press, Inc. (London), Ltd., London.
- Drouhet, E., and B. Dupont. 1983. Laboratory and clinical assessment of ketoconazole in deep-seated mycoses. Am. J. Med. **74**:30–47.
- Gams, W. 1971. Cephalosporium-artige schimmelpilze. Gustav Fischer Verlag, Stuttgart, Federal Republic of Germany.
- Kornerup, A., and J. H. Wanscher. 1978. Methuen handbook of color, 3rd ed. Methuen, London.
- Laverde, S., L. H. Moncada, A. Restrepo, and C. L. Vera. 1973. Mycotic keratitis; 5 cases caused by unusual fungi. Sabouraudia **11**:119–123.
- Matsumoto, T., J. Masaki, and T. Okabe. 1979. *Cylindrocarpon tonkinense*: as a cause of keratomycosis. Trans. Br. Mycol. Soc. **72**:503–504.
- McGinnis, M. R., and M. G. Rinaldi. 1985. Antifungal drugs: mechanisms of action, drug resistance, susceptibility tests, and assays of activity in biological fluids, p. 223–281. In V. Lorian (ed.), Antibiotics in laboratory medicine, 2nd ed. The Williams & Wilkins Co., Baltimore.
- Nelson, P. E., T. A. Toussoun, and W. F. O. Marasas. 1983. *Fusarium* species. An illustrated manual for identification. The Pennsylvania State University Press, University Park.
- Padhye, A. A., A. S. Sekhon, and J. W. Carmichael. 1973. Ascocarp production by *Nannizzia* and *Arthroderma* on keratinous and non-keratinous media. Sabouraudia **11**:109–114.
- Palestine, R. F., and R. S. Rogers. 1982. Diagnosis and treatment of mycetoma. J. Am. Acad. Dermatol. **6**:107–111.
- Rinaldi, M. G., and A. W. Howell. 1988. Antifungal antimicrobics: laboratory evaluation, p. 325–356. In B. B. Wentworth (ed.), Diagnostic procedures for mycotic and parasitic diseases, 7th ed. American Public Health Association, Washington, D.C.
- Rippon, J. W. 1988. Medical mycology, 3rd ed., p. 732–735. The W. B. Saunders Co., Philadelphia.
- Samuels, G. J. (New York Botanical Garden, Bronx). 1987. Personal communication.
- Samuels, G. J., and D. Brayford. 1990. Variation in *Nectria radicolica* and its anamorph, *Cylindrocarpon destructans*. Mycol. Res. **94**:433–442.
- Summerbell, R. C., S. E. Richardson, and J. Kane. 1988. *Fusarium proliferatum* as an agent of disseminated infection in an immunocompromised patient. J. Clin. Microbiol. **26**:82–87.
- Visvanathan, R. 1989. Surgical treatment of fungal mycetoma. Can. J. Surg. **32**:74–76.