

PITUITARY CYSTADENOMA, ENTEROLIPIDOSIS, AND CUTANEOUS MYCOSIS IN AN EVERGLADES RATSNAKE (*ELAPHE OBSOLETA ROSSALLENII*)

Liza I. Dadone, V.M.D., Eric Klaphake, D.V.M., Dipl. A.C.Z.M., Dipl. A.B.V.P. (Avian), Michael M. Garner, D.V.M., Dipl. A.C.V.P., Denise Schwahn, D.V.M., Ph.D., Dipl. A.C.V.P., Lynne Sigler, M.Sc., John G. Trupkiewicz, D.V.M., Dipl. A.C.V.P., Gwen Myers, D.V.M., and Michael T. Barrie, D.V.M.

Abstract: An 11-yr-old captive-born male Everglades ratsnake (*Elaphe obsoleta rossalleni*) presented with dysecdysis, hyperkeratosis, and inappetance. Two skin biopsies demonstrated a diffuse hyperkeratosis with both a bacterial and fungal epidermitis. *Fusarium oxysporum* was cultured from both biopsies and considered an opportunistic infection rather than a primary pathogen. Medical management was unsuccessful, and the snake was euthanized. Histologic findings included a pituitary cystadenoma arising from the pars intermedia, severe intestinal lipodosis, generalized epidermal hyperkeratosis, and lesions consistent with sepsis. It is hypothesized that endocrine derangements from the pituitary tumor may have caused the skin and intestinal lesions.

Key words: Cutaneous mycosis, Everglades ratsnake (*Elaphe obsoleta rossalleni*), *Fusarium oxysporum*, intestinal lipodosis, pituitary cystadenoma.

BRIEF COMMUNICATION

Generalized dysecdysis or hyperkeratosis in snakes is often associated with inappropriate husbandry conditions and occasionally with other diseases. Prolonged exposure to low ambient temperatures can cause immunosuppression, which may lead to secondary opportunistic skin infections and dysecdysis.² Inappropriate humidity or substrate can cause dehydration, which then prevents normal fluid accumulation in the skin cleavage zone during the molting process.² In malnourished snakes, decreased production of enzymes needed for the shedding cycle may result in retained sheds.² Dysecdysis occasionally occurs with primary fungal or bacterial infections, and

diseases that interfere with hormone cascades involving the pituitary, thyroid, and/or adrenal glands.² This report documents a pituitary cystadenoma in a ratsnake associated with hyperkeratosis, generalized dysecdysis, and intestinal lipodosis.

An 11-yr-old captive-born male Everglades ratsnake (*Elaphe obsoleta rossalleni*) had a 2-mo history of generalized cutaneous hyperkeratosis and inappetance. Husbandry was consistent with species recommendations, and the other snakes in the exhibit had no clinical signs of disease. On initial examination (Day 1), all scales were thickened and retained with dry erosive areas between scales. The snake was bright and alert but had a slowed righting reflex of the caudal one-third of the body, suggestive of ataxia. The snake was soaked in warm water for 2 hr q72h, treated with ceftazidime antibiotics (Fortaz, GlaxoSmithKline, Research Triangle Park, North Carolina 27709, USA; 25 mg/kg i.m., q72h), and placed in an ambient humidity of 60%.

On Day 14, a complete blood count (CBC) and plasma biochemistry panel showed a marginally elevated lymphocyte count (lymphocytes = 9,700/ μ l; International Species Information System reference range 4,052 \pm 3,734; manual count from blood smear, biochemistry IDEXX Laboratories, Westbrook, Maine 04092 USA). Radiographs showed mild mid-body vertebral osteoarthritis and mild gas distention in the caudal third of the gastrointestinal tract. The slowed righting reflex may have been, at least in part, due to osteoarthritic changes.

On Day 21, the snake was placed under general anesthesia using sevoflurane gas (SevoFlo, Ab-

From the Columbus Zoo and Aquarium, 9990 Riverside Drive, P.O. Box 400, Powell, Ohio 43065, USA (Dadone, Myers, Barrie); ZooMontana, 2100 South Shiloh Road, Billings, Montana 59106, USA (Klaphake); Northwest ZooPath, 654 West Main Street, Monroe, Washington 98272, USA (Garner, Trupkiewicz); Department of Veterinary Biosciences, The Ohio State University, 1925 Coffey Road, Columbus, Ohio 43210, USA (Schwahn); and the University of Alberta Microfungus Collection and Herbarium, Devonian Botanic Garden, Edmonton, Alberta T6G-2R3, Canada (Sigler). Present addresses (Dadone): Cheyenne Mountain Zoo, 4250 Cheyenne Mountain Zoo Road, Colorado Springs, Colorado 80906, USA; (Schwahn): Comparative Pathology Laboratory, Research Animal Resources Center, 1710 University Avenue, Madison, Wisconsin 53726, USA. Correspondence should be directed to Dr. Dadone (liza@dadonevet.com).

bott Laboratories, Illinois 60064, USA), and a skin biopsy was collected for histologic examination and culture. The biopsy was collected from the laterodorsal caudal third of the body and closed with 4-0 polydioxanone everting sutures (PDS-II, Ethicon, Inc., Somersville, New Jersey 08876, USA). Ceftazidime antibiotic was continued every 3 days as previously described, and meloxicam (Metacam Solution for Injection, Boehringer Ingelheim Vetmedica, Inc., St. Joseph, Missouri 64506, USA; 0.1 mg/kg i.m., q48h for 3 doses) was administered for pain management.⁵

Histologic examination revealed multifocal suppurative (heterophilic) dermatitis with intracorneal 2–3 μm diameter fungal hyphae. The fungal hyphae had regular septae, parallel walls, and rare branching. The epidermis was hyperplastic and had a diffuse hyperkeratosis with mixed orthokeratosis and parakeratosis, and vacuolar degeneration located predominantly between scales. Subcorneal vesicles were associated with small numbers of adherent or intracorneal bacteria (The Ohio State University, Department of Veterinary Biosciences, Columbus, Ohio 43210, USA). Aerobic bacterial cultures grew 2+ *Enterococcus* sp., 2+ *Escherichia coli*, and 2+ *Bacillus* sp., and fungal cultures grew both *Fusarium* and *Alternaria* species (IDEXX Laboratories).

On Day 28, a second skin biopsy was collected and again grew *Fusarium* species as well as *Clonostachys rosea*. The *Fusarium* was identified as *F. oxysporum* by sequencing of the ribosomal ITS region as previously described⁸ and by a 100% match to sequences of *F. oxysporum* on deposit in GenBank. The isolate and the sequence are banked as UAMH 10871 and Genbank FJ184276, respectively.

Following the second biopsy, the snake was treated with itraconazole via gastric tube (Sporanox Oral Solution, Ortho Biotech, Inc., Raritan, New Jersey 08869, USA; 5 mg/kg s.i.d. for 1 wk, 2 wk break, then s.i.d. for 1 wk). Pulsatile treatment with itraconazole was selected to minimize possible toxic effects.⁷ The snake was tube fed after each itraconazole treatment, and every 3 days during non-treatment weeks (Carnivore Care, Oxbow Enterprises, 29012 Mill Road, Murdock, Nebraska 68407, USA; 20 ml s.i.d.), and intracoelomic fluids with 2.5% dextrose were given (Lactated Ringer's Injection, United States Pharmacopeia [USP], Hospira Inc., Lake Forrest, Illinois 60045, USA; 20 ml/kg q72h).

Despite medical and nutritional support, the snake's condition deteriorated, and the animal became polydipsic. A Day-45 CBC and plasma

chemistry panel showed a marked lymphocytic leukocytosis (total white blood count [WBC] = 64,500 cells/ μL , ISIS reference range 9,316 +/- 6,428; lymphocytes = 52,330/ μL ; IDEXX Laboratories). On Day 50, the second wk of itraconazole treatment was begun as per the pulsatile treatment regimen. After 3 additional treatments, the snake became minimally responsive and was humanely euthanized.

Gross necropsy revealed poor body condition with moderate dehydration and generalized epidermal hyperkeratosis. Lung parenchyma was thickened, and there was mucoid material within the airway in the cranial aspect of the lung. The proximal third of the small intestine had a markedly thickened mucosa, with white-yellow discoloration (Fig. 1). Tissues, including the entire head, were collected and fixed in 10% neutral buffered formalin. The head was decalcified and serially sectioned transversely. No gross lesions were visible in the brain or pituitary gland. Representative sections of the head and soft tissues were submitted for standard processing and hematoxylin and eosin staining (H&E). Gomori methenamine silver (GMS) for fungi was applied to skin sections. Oil red O stain for lipid was applied to formalin-fixed, snap-frozen tissue sections taken from the thickened region of the small intestine.

Histologically, the skin had marked diffuse epidermal hyperplasia, hyperkeratosis with mixed orthokeratosis and parakeratosis, and multifocal serocellular crusts. The crusts were colonized with a moderate mixed population of cocci and small bacilli, and with numerous fungal hyphae that were argyrophilic and had morphologic features as previously described in the biopsy specimens. The proximal small intestine had severe diffuse mucosal epithelial microvacuolar change; the Oil red O stain revealed that the vacuoles contained lipid (Fig. 1b, c). The lamina propria of the proximal small intestine was infiltrated by small numbers of lymphocytes and plasma cells and rare granulocytes. Expanding the pars intermedia and compressing the surrounding pituitary gland was a well-demarcated, unencapsulated, expansile mass that replaced approximately one-half of the gland. The pituitary mass was composed of papillary infoldings of cuboidal to columnar cells lining cystic cavities containing proteinaceous fluid (Fig. 2). Cell morphology was artifactually altered due to the decalcification process, but in general, the cells appeared to be well differentiated, with basal nuclei and few or no cytoplasmic granules. The

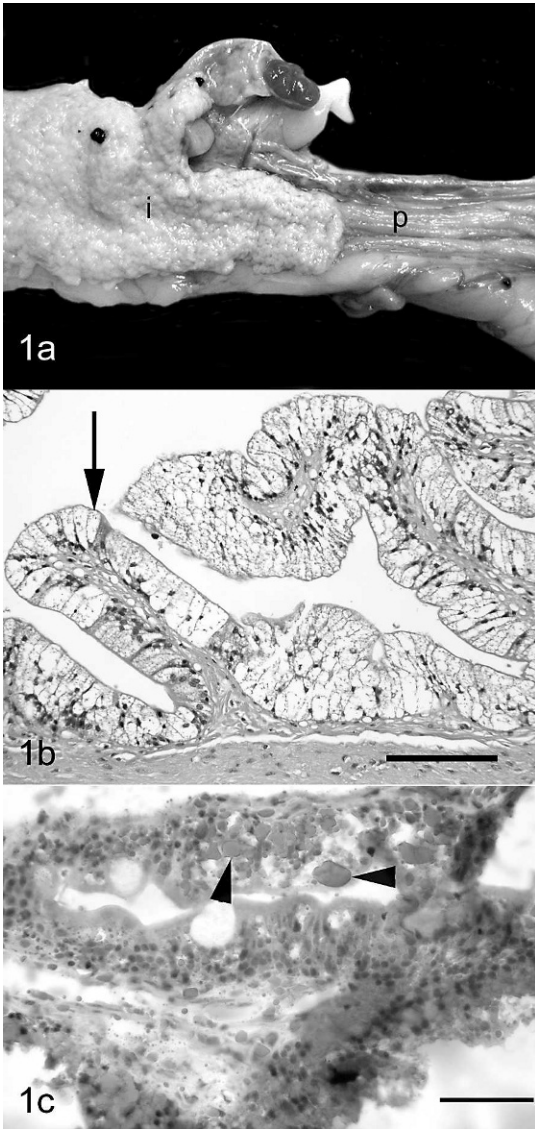


Figure 1. Intestine, rat snake. **a.** Note abrupt transition from normal pylorus (p) to markedly thickened mucosa of small intestine (i). **b.** Histologic section of small intestine showing markedly vacuolated epithelium lining the villi (arrow). H&E. Bar = 200 μ m. **c.** Numerous intracytoplasmic vacuoles that stain positive for lipid (arrowheads) are within the enterocytes. Oil red O stain. Bar = 160 μ m.

histomorphology of the mass was consistent with a cystadenoma. No invasion of the adjacent pituitary or surrounding tissues was identified. The interrenal cells of the adrenal glands were hypertrophied and vacuolated. Additional findings included mild lymphocytic, heterophilic periportal to random hepatitis, moderate proliferative interstitial pneumonia with inspissated

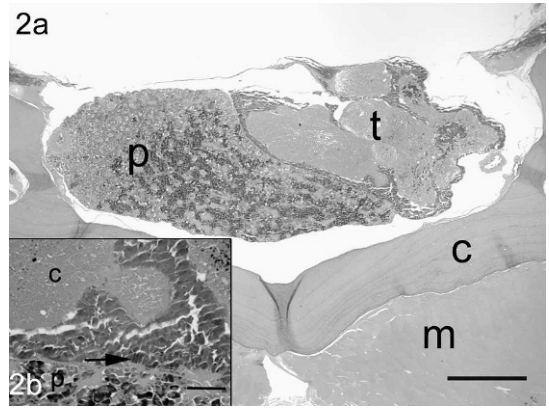


Figure 2. Pituitary, rat snake. Note tumor (t) occupying a large part of the pituitary (p) but with no invasion of the adjacent pituitary parenchyma, calvarium (c), or muscle (m). H&E. Bar = 425 μ m. Inset: tumor and underlying normal pituitary (p). Note columnar epithelium of tumor (arrow) forming papillary folds that extend into cystic cavity (c) filled with proteinaceous fluid. H&E. Bar = 150 μ m.

edema, mild heterophilic epicarditis, and moderate sclerotic change in a great vessel.

Banked plasma from 1 mo prior to euthanasia and from the day of euthanasia was submitted for endogenous adrenocorticotrophic hormone (ACTH) level analysis (Michigan State University, East Lansing, Michigan, USA). Plasma from a healthy clutch-mate was also analyzed for comparison. There was no obvious difference in ACTH levels among the 3 submitted samples (patient initial ACTH = 3.0 pmol/L; patient final ACTH = 4.0 pmol/L; sibling ACTH = 3.8 pmol/L; Michigan State University).

Pituitary neoplasms in snakes appear to be rare. Two prior cases of pituitary adenomas occurred in boids.^{3,4} The current report is the first to describe a pituitary gland neoplasm in a colubrid snake. In all three cases, snakes were middle-aged or older and presented with a slowed righting reflex but shared no other obvious clinical signs. The location of the pituitary lesion was different in each of the three cases with one confined to the pars distalis,⁴ one arising from the pars intermedia and expanding into the pars nervosa,³ and the mass in this report involving only the pars intermedia. Neither of the previous reports identified cyst formation within the described adenomas. In the authors' experience, the brain and pituitary gland are often not evaluated histologically when neurologic clinical disease is not clearly evident, thus pituitary tumors may be underreported rather than rare as indicated by the literature.

In the snake in this report, cystadenoma compression of the surrounding pituitary gland likely compromised normal physiologic pituitary gland function. The neoplastic pituitary cells were well differentiated, indicating the tumor was potentially secretory or functionally active. The ACTH serum concentration values from the snake described in this report and a clinically normal clutch mate were similar. Interpretation is difficult due to the lack of data on normal ACTH levels. If there is pulsatile release of ACTH in snakes, as is common in mammals, it is possible that the collection times of the two analyzed serum samples did not represent such pulsatile release by the cystadenoma (Kent Refsal, pers. comm., November 2007). In anole lizards (*Anolis carolinensis*), exogenous ACTH decreases ecdysis frequency,¹ so pulsatile release of ACTH in this case may have contributed to dysecdysis.

The profound enteric lipidosis may have caused a clinical enteropathy. While enterocyte lipidosis is uncommon in reptiles, it is occasionally seen in fish and birds (M. Garner, unpubl. data, June 2009). The pathogenesis is not understood but could be related to endocrine derangements or overnutrition. In this case, review of the nutritional support was not consistent with overfeeding. Speculatively, hormone secretion from the cystadenoma may have altered lipid metabolism leading to intracellular lipid accumulation in the enterocytes. Future research may clarify whether hormones such as ACTH or thyroid-stimulating hormone (TSH) could alter lipid metabolism and cause enteric lipidosis).

The *Fusarium* isolate is the probable cause of the cutaneous mycosis, because both skin biopsies yielded this fungus and histology revealed hyaline hyphae having morphology consistent with *Fusarium* species. *Fusarium oxysporum* and other *Fusarium* species have been documented as the cause of cutaneous and deep mycoses in reptiles⁶ and have also been found on shed skins.⁶ In the present case, the *Fusarium* infection was likely opportunistic and not the primary cause of the dysecdysis. The other fungi grown (*Alternaria* species, *Clonostachys rosea*) are common soil fungi and are considered contaminants because each was grown from only one biopsy specimen.

Hypertrophy and vacuolation of adrenal gland interrenal cells is typical of a chronic stress response but potentially could have been caused by hormones released from the pituitary cystadenoma. The adrenal lesions suggest the snake was immunosuppressed, which could have led to subsequent opportunistic fungal and bacterial

skin infections. The bacteria cultured from the skin biopsies are considered fecal or soil contaminants and not the primary cause of the dysecdysis, but appear to have caused secondary systemic infection. The lesions in the lung, liver, and heart are suggestive of ongoing sepsis.

Further investigation is needed to understand pituitary hormones in reptiles, and their potential to cause chronic dysecdysis or enteric lipidosis. This case emphasizes the importance of including the head of reptiles for postmortem histologic review.

Acknowledgments: The authors thank the veterinary technologists and reptile keepers at the Columbus Zoo for assistance with medical workup and patient care; Dr. Kent Refsal, D.V.M., Ph.D., at Michigan State University for assistance interpreting ACTH results; and Deb Krum for help with the literature search. The authors also thank Roy Brown of Histologic Consulting Service for the excellent slide and stain preparations, and Jamie Kinion and Christie Buie of Northwest ZooPath for data retrieval and photo editing, respectively.

LITERATURE CITED

1. Chiu, K. W., and W. G. Lynn. 1970. The effect of ACTH on the sloughing frequency of normal and thyroidectomized *Anolis carolinensis* (Iguanidae, Lacerilia). *Biol. Bull.* 138: 129–137.
2. Fitzgerald, K. T., and R. Vera. 2006. Dysecdysis. *In:* Mader, D. R. (ed.). *Reptile Medicine and Surgery*, 2nd ed. Saunders Elsevier, St. Louis, Missouri. Pp. 778–786.
3. Gyimesi, S. S., and M. M. Garner. 2007. Pituitary adenoma in a Dumeril's ground boa, *Acrantophis dumerili*. *J. Herpetol. Med. Surg.* 17: 16–18.
4. Linn, M. J., T. McNamara, J. J. Seiberger, and Y. Kress. 1996. Pituitary adenoma in a black-headed python (*Aspidites melanocephalus*). *Proc. Am. Assoc. Zoo Vet. Annual meeting 1996:* 449 (Abstract).
5. Martinez-Jimenez, D., and S. J. Hernandez-Divers. 2007. Emergency care of reptiles. *Vet. Clin. N. Am. Exot. Anim. Pract.* 10: 557–585.
6. Paré, J. A., and E. R. Jacobsen. 2007. Mycotic diseases of reptiles. *In:* Jacobson, E. R. (ed.). *Infectious Diseases and Pathology of Reptiles: Color Atlas and Text*. CRC Press, Boca Raton, Florida. Pp. 527–570.
7. Riviere, J. E., and M. G. Papich. 2009. Chemotherapy of microbial diseases. *In:* *Veterinary Pharmacology and Therapeutics*, 9th ed. John Wiley & Sons, Ames, Iowa. P. 1026.
8. Sigler, L., and C. F. C. Gibas. 2005. Utility of a cultural method for identification of the ericoid mycobiont *Oidiodendron maius* confirmed by ITS sequence analysis. *Stud. Mycol.* 53: 63–74.

Received for publication 29 June 2009