

***Chrysosporium* anamorph of *Nannizziopsis vriesii* associated with fatal cutaneous mycoses in the salt-water crocodile (*Crocodylus porosus*)**

A. D. THOMAS*, L. SIGLER†, S. PEUCKER*, J. H. NORTON* & A. NIELAN‡

*Department of Primary Industries, Animal and Plant Health Service, Oonoonba Veterinary Laboratory, P.O. Box 1085, Townsville, Queensland 4810, Australia; †University of Alberta Microfungus Collection, Devonian Botanic Garden, Edmonton, Alberta T6G 2E1, Canada; ‡Edward River Crocodile Farm, P.O. Pomppuraaw, Queensland 4871, Australia

The *Chrysosporium* anamorph of *Nannizziopsis vriesii*, recently identified as the cause of cutaneous infections in chameleons and brown tree snakes, was associated with skin infections and deaths in salt-water crocodile (*Crocodylus porosus*) hatchlings on two separate occasions 3 years apart. In all, 48 animals died from the infection. All hatchlings came from the same farm in northern Queensland, Australia.

Keywords *Chrysosporium*, crocodylians, dermatomycosis, reptile infection

Introduction

Jacobson *et al* [1] recently reviewed the published reports of fungal infections in crocodylians. Most reports of cutaneous and deep infections have incriminated common environmental moulds such as *Fusarium* or *Paecilomyces* species, but causative agents are often incompletely identified and it can be difficult to evaluate whether the isolated fungus is present as a contaminant or involved in a pathologic process. There are few prior reports of fungal diseases among crocodiles in Australia and most concern farm-reared animals. *Paecilomyces lilacinus* [2] and *Fusarium solani* [3] were identified as the cause of systemic infection in salt-water crocodile hatchlings (*Crocodylus porosus*). A survey of farmed salt-water (*C. porosus*) and fresh-water (*C. johnsonii*) crocodiles identified fungi as a significant cause of skin lesions, but no single fungus was determined to be the cause of infection [4,5]. *Fusarium* sp. was the most common fungus isolated, but isolates belonging to the genera *Aspergillus*, *Penicillium*, *Curvularia*, *Syncephalastrum*, *Candida* and *Trichosporon* were also obtained. Dermatophytes are the predominant cause of cutaneous

disease in mammals [6], but these fungi are rarely implicated in reptile disease [1,7]. A few reports of mycotic infection in lacertilians and ophidians have identified keratinophilic species of soil origin belonging to the genera *Trichophyton* and *Chrysosporium* [8–12] but there have been no prior reports of members of these genera infecting crocodylians [1,3,5,13,14]. However, infection by these keratinophilic fungi is difficult to prove as they are common inhabitants in the soil [6,15] and may be carried as dormant propagules on the hairs, skins or feathers of healthy mammals, reptiles and birds [16–18]. Recently, the *Chrysosporium* anamorph of *Nannizziopsis vriesii* has been identified as the cause of skin infections in three species of chameleons [7] and in captive brown tree snakes [19]. We describe an outbreak of fatal mycotic dermatitis in saltwater crocodile hatchlings associated with this fungus [20]. These animals were part of a trial that investigated the use of pellets as a nutritional feed for crocodiles.

Case report

History

Case 1

The Oonoonba Veterinary Laboratory (OVL), Townsville, has an environmentally controlled research facility for studying the salt-water crocodile, *C. porosus*. There are six rooms each containing two sloping tanks allowing

Correspondence: Annette D. Thomas, Oonoonba Veterinary Laboratory, P.O. Box 1085, Townsville, Queensland 4810, Australia. Tel.: +61 7 4722 2604; fax: +61 7 4778 4307; e-mail: thomasa@dpi.qld.gov.au.

for both land and water areas. Both air and water temperature can be maintained within set parameters.

In 1994, 247 hatchlings from six clutches (89, 90, 96, 99 hatched on 11 May; 102, 103 hatched on 24 May) were transported in two deliveries to OVL. Animals were maintained in separate tanks for 4 weeks to acclimatize them to the conditions of water temperature at 32 °C and air temperature at 30 °C. After this time, they were tagged, weighed and measured. The average weight of the hatchlings was 61.3 g. Several of the hatchlings from clutch 89 initially had white flaky areas on the underside of the body and back of the thighs. During the first month of acclimatisation, there was an electrical malfunction that resulted in a drop in the water temperature of all tanks down to 22 °C overnight although the air temperature remained at 30 °C. The fault was remedied the next morning. However, within 2–3 days of this problem, a creamy, caseous mass was noticed on, and occasionally under, the scales of the head, back and feet of several of the 34 crocodiles from clutch 89. Four animals were swabbed for culture. Within 7–14 days, the animals were more severely affected and the infection took the form of a leathery, plaque-like lesion that spread over the snout, under the jaw and along the legs. Most of the animals in this tank (clutch 89) were affected; however the crocodiles in the other tank situated in the same environmentally controlled room were unaffected. In all, 10 crocodiles died over a 14–16-day period. Twelve samples were collected for culture and histopathology from these 10 animals; two animals were sampled twice at 3 days and 7 days after lesions were first noticed. The nutritional trial was delayed for 8 weeks while treatment was introduced.

When the infection appeared to be under control, the tanks were cleaned with aricide (Rural West Pty Ltd, Bentley, Western Australia, Australia) before re-use. The trial recommenced with a weighing, measuring and sorting of the animals by weight into 11 groups (six groups containing animals from clutches 89, 90 and 103 and five groups containing those from clutches 96, 99 and 102). These new groups were then distributed into 11 tanks with water temperatures ranging from 26 ° to 34 °C at intervals of 2 °C, and air temperatures ranging from 28 ° to 32 °C (also at 2 °C intervals). This was a statistical trial and there were two replicates with water temperature at 26 °C and air temperature at 28 °C.

One month after the trial had commenced, five animals in one of the 26 °C tanks (which was a different tank from that where the original outbreak occurred) developed plaque-like lesions that were more severe than the previous time. Samples were taken for microbiological culture. The 18 crocodiles in this tank had been mixed from clutches 96, 99 and 102. Eleven animals

died over a 23-day period before the infection was brought under control.

Case 2

In 1997, at the farm from where the 1994 hatchlings were obtained, 85 hatchlings from five clutches were placed together in the one pen for growth to juvenile stage. These were added to the pen on 9 May (28 hatchlings), 12 May (51) and 19 May (6). Within a month of placement, 30 were dead with plaque-like lesions similar to those registered at OVL in 1994. The mortalities occurred over a 16-day period and peaked with 13 deaths on the 12th day. Three live hatchlings with lesions were sent to OVL for examination.

Necropsy and sampling

Plaque-like lesions were removed aseptically as possible and cultured for both bacteria and fungi. Dead crocodiles were also necropsied and skin, heart, liver and/or brain, were removed for culture and/or histopathology. Visual observation by the handlers on the farm during the second case study indicated that the lesions on the 33 animals that died were similar to those observed in the 1994 outbreak at OVL.

Samples were macerated using a Stomacher blender (Stomacher Lab-Blender 80, Seward Medical, London, UK) and cultured onto blood agar and MacConkey agar (Oxoid Australia Pty Ltd, West Heidelberg, Victoria, Australia), lysine–mannitol–glycerol (LMG) agar [21] and into buffered peptone water (Oxoid) to isolate aerobic bacteria including *Salmonella* spp. The plates were incubated at 37 °C. After 24 h, a drop of the buffered peptone water was inoculated into Rappaport–Vassiladis broth (Oxoid) and 24 h later, a drop of this medium was inoculated onto another LMG plate. The plates were incubated at 37 °C for 2 days. Isolates were purified where necessary and identified using conventional tests or kit tests such as the Microbact 24E (Medvet Science Pty Ltd, Adelaide, South Australia, Australia) or API 20E (bioMérieux, Marcy, l'Etoile, France) systems.

Samples were also plated onto Sabouraud dextrose agar with added gentamicin and chloramphenicol (SDA) and mycosel agar with thiamine (MAT) (both Oxoid) and incubated at 28 °C for 10–14 days in plastic boxes to prevent drying of the agar. Fungal isolates were identified by microscopic examination of tease and slide culture preparations.

Histopathology and electron microscopy

Tissues for histopathology were stained with either haematoxylin and eosin (H&E) or Grocott–Gomori's

methenamine silver stain (GMS). For scanning electron microscopy (SEM), a portion of the culture was fixed in 2% osmium tetroxide vapour and dried to the critical point. The material was examined with an S-2500 Hitachi SEM.

Pathology

Case 1

Gross pathology. The hatchling crocodiles developed leathery plaque-like lesions, mainly on the head, jaw and legs. These lesions progressed over a 2-week period. Plaques reached sizes of 1–2 cm in length and these could be peeled off the skin leaving white to reddened areas underneath.

Histopathology. The skin lesions consisted of epidermal hypertrophy and hyperplasia, with ballooning of the epidermal cells. This tissue appeared necrotic and contained dead inflammatory cells. There was loss of the germinal epithelium where the full depth of the epidermis had been destroyed. The dermal melanophore layer was absent or much reduced beneath areas of epidermal necrosis. Minimal inflammation was observed in the hypodermis. The GMS demonstrated large numbers of hyaline, branching, septate fungal hyphae, 2–4 μm in width, in the necrotic tissue (Fig. 1). Arthroconidia, measuring 1.5–2 μm in width and 2–3 μm in length, occurred in groups in the outer regions of the necrotic areas (Fig. 2). The fungus was limited to the necrotic epidermal tissue. In a few sites the fungus had penetrated through the dermis and hypodermis up to the edge of the muscle tissue. The liver was fatty and there was some inflammation around the portal triads. Other tissues were not examined.

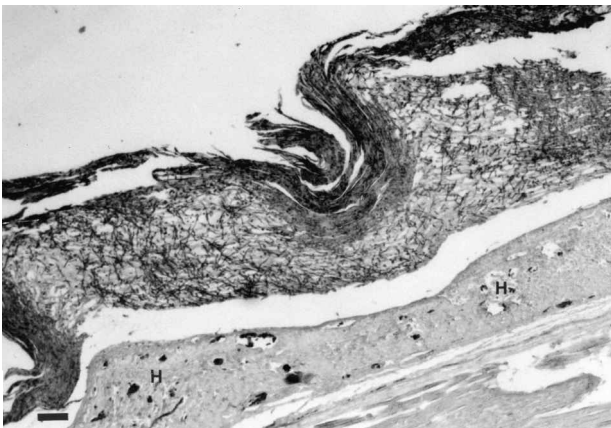


Fig. 1 A section of skin showing a heavy infestation of the epidermis with fungal hyphae. Note the lack of inflammation in the hypodermis (H). GMS. Scale bar, 100 μm .

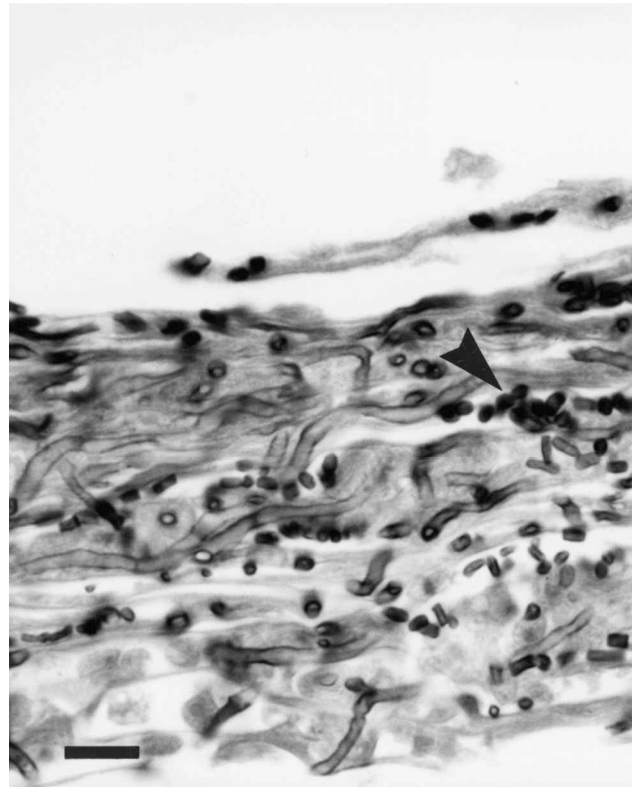


Fig. 2 A section of the necrotic skin lesion from Figure 1 to demonstrate collections of arthroconidia (arrows). GMS. Scale bar, 15 μm .

Case 2

Gross pathology. The three juvenile crocodiles had focal skin lesions 1–2 cm in diameter on their ventral surfaces. The affected skin had a dull appearance. When the necrotic epidermis was removed, a white surface was left beneath. Lesions were observed on the under surfaces of the jaw, the abdomen, the tail, the limbs and the feet.

Histopathology. The epidermal lesions were similar to those in case 1 above. However, in some lesions where there was only partial destruction of the epidermal layers, a heavy mononuclear cell inflammation was often seen in the hypodermis (Fig. 3). No other tissues were examined.

Microbiology

Case 1

During the first outbreak, a fungus superficially resembling *Chrysosporium* species or *Trichophyton mentagrophytes* was isolated from the plaques removed from all the 10 crocodiles that died throughout the infection period (Table 1). This fungus was relatively fast growing on SDA with pale yellowish-white powdery colonies that formed small (3 μm diameter), globose to clavate

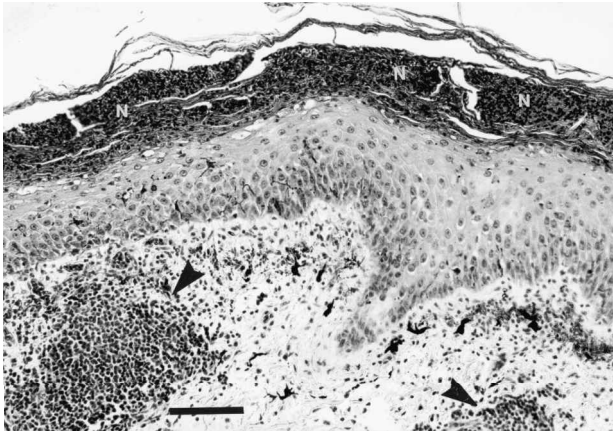


Fig. 3 A section of skin to show partial necrosis (N) of the epidermis. A heavy mononuclear inflammatory cell response (arrow) is present in the hypodermis. H&E. Scale bar, 100 μ m.

conidia and arthroconidia. *Pseudomonas aeruginosa* was isolated from the same animals. Different fungi and bacteria were isolated from the skin and plaque samples of only some hatchlings. No organisms were recovered from the heart, liver or brain.

In the second outbreak, among the 11 crocodiles that died during the trial period, only five had indications of plaques on the head, back or feet. Cultures of these lesions yielded a fungus similar to that isolated during the first outbreak (Table 2). Other fungi and bacteria were isolated from skin samples of 10/11 animals (Table 2). *F. solani* was isolated from the same five animals and from skin of five additional hatchlings, but this fungus, in conjunction with *P. lilacinus*, was also isolated from the backs of hatchlings in a number of the tanks in various rooms where the infection did not occur (data not shown). Samples of heart were taken from each of the crocodiles and cultured for aerobic bacteria and for

fungi. No fungus was isolated from any animal. *Aeromonas hydrophila* was isolated from the heart of four crocodiles; in two of these animals the *Chrysosporium* fungus was isolated from skin plaques.

Case 2

The same *Chrysosporium* fungus was isolated from lesions on the head, abdomen, legs and feet of all three of the sick hatchlings sent to the laboratory. However, *F. solani* was recovered also from plaque samples taken from two of the three hatchlings. No bacteria were cultured from the heart, liver or brain of these animals.

Mycology

Three isolates of the *Chrysosporium* fungus obtained from the plaque lesions were referred to the University of Alberta Microfungus Collection and Herbarium (UAMH), Edmonton, Canada, where they were identified as the *Chrysosporium* anamorph of *N. vriesii*, based on comparison with prior isolates obtained from reptile mycoses and with the ex-type culture of *N. vriesii* [7,19]. The isolates were deposited as accession numbers UAMH 9664, 9665, 9666 and examined using methods previously described [7,19]. They produced yellowish-white, velvety to powdery, sometimes strongly zonate colonies reaching diameters of 3.5–3.8 cm on potato dextrose agar (PDA, Difco, Becton Dickinson Microbiology Systems, Sparks, Maryland, USA) after 14 days at 30 °C (Fig. 4). Growth was slightly slower at 25 °C and no growth occurred at 37 °C. Other growth features included tolerance to cycloheximide at 400 μ g ml⁻¹, a positive urease reaction within 5 days, slow growth with a strong clearing of milk solids and no pH change after 11 days on Bromcresol purple–milk solids–glucose agar, and digestion of hairs with perforating bodies within 14 days [6,7,19]. Within 2–3 weeks of incubation at

Table 1 Fungal and bacterial isolates from skin plaques on 10 crocodile hatchlings belonging to clutch 89

	Crocodile									
	602	617	624	627	629	633	637	651	661	667
Fungi										
<i>Chrysosporium</i> anamorph of <i>N. vriesii</i>	+	+	+	+	+	+	+	+	+	+
<i>F. solani</i>		+	–	+	–	+	+	–	–	–
<i>P. lilacinus</i>	–	–	–	–	+	–	–	+	+	–
Bacteria										
<i>Aeromonas hydrophila</i>	+	+	–	–	–	+	+	–	–	+
<i>A. sobria</i>	–	–	–	–	–	+	+	–	–	–
<i>Pseudomonas aeruginosa</i>	+	+	+	+	+	+	+	+	+	+
<i>Serratia marcescens</i>	+	+	–	–	–	–	–	–	–	+
Enterobacters	–	+	–	–	–	–	–	–	–	–

Table 2 Bacterial and fungal isolates from skin lesions and heart removed from 11 crocodile hatchlings belonging to clutches 96 (hatchlings 403–461), 99 (hatchlings 321–390) and 102 (hatchling 769)

	Crocodile														
	403	413	427	441	461	321	326	343		363		390		769	
	S	S	S	S	S	S	S	H	S	H	S	H	S	S	H
Fungi															
<i>Chrysosporium</i> anamorph of <i>N. vriesii</i>	-	-	+	-	-	+	-	-	+	-	+	-	+	-	-
<i>F. solani</i>	-	+	+	+	+	+	+	-	+	-	+	-	+	+	-
Bacteria															
<i>A. hydrophila</i>	-	-	-	-	-	-	+	+	+	+	+	+	+	+	+
<i>Ps. aeruginosa</i>	-	+	-	-	+	-	+	+	+	-	-	-	+	+	-
Enterobacters	-	+	+	+	+	-	+	-	-	-	+	+	+	+	-
Plaques	-	-	+	-	-	+	-	-	+	-	+	-	+	-	-

S, skin lesion or skin swab; H, heart samples yielding positive cultures; no bacteria or fungi were isolated from heart samples of other hatchlings.

30 °C, colonies on PDA and on oatmeal–salts agar [6] began to develop globose, buff-coloured ascomata-like structures visible to the naked eye (Fig. 5). Microscopic examination revealed that these structures, sometimes called pseudogymnothecia, were composed of branched asperulate hyphae surrounding masses of conidia (Fig. 6). No ascospores were produced in cultures held for several months or when crocodile isolates were mated with each other. Conidia (aleurioconidia) formed on the sides of the hyphae (sessile) or on swollen cells either on the vegetative hyphae (Fig. 7) or on the hyphae composing the pseudogymnothecium (Fig. 6). The conidia were subglobose, hyaline, smooth and single-celled. Arthroconidia were also formed, sometimes from undulate lateral branches (Fig. 7).

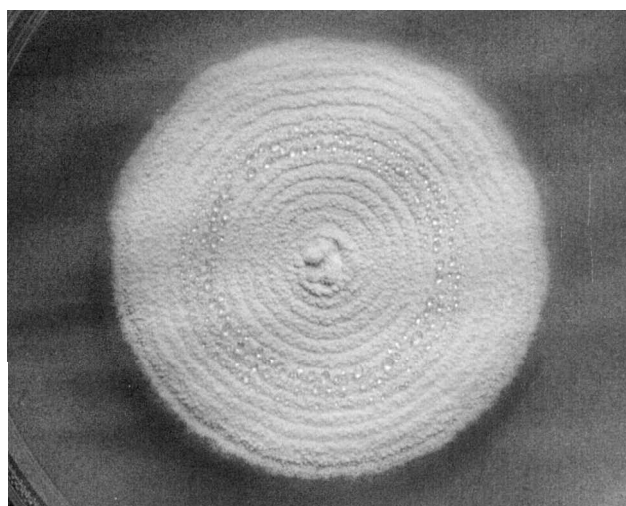


Fig. 4 Colony of the *Chrysosporium* anamorph of *Nannizziopsis vriesii* on potato dextrose agar after 21 days at 30 °C (UAMH 9664).

Treatment

Case 1

All 12 tanks in the six environmentally controlled rooms were receiving formalin in the water at the rate of 0.003% to control the growth of *Fusarium* spp. and *P. lilacinus* which are known to occur as contaminants on crocodiles. After the lesions were recognized as a serious threat to the hatchlings, the first treatment was a salt-water bath for 7 min; however, this did not have any great effect and only irritated the crocodiles. The best treatment was a combination of removal of the plaques followed by swabbing of the reddened area with the iodine-based antiseptic Betadine (Faulding Pharmaceuticals, Salisbury, South Australia, Australia). The crocodiles were allowed to dry out in containers for several hours before placing them back into the tank that had been cleaned out with aracide. Formalin was then added



Fig. 5 Close-up view of the *Chrysosporium* anamorph of *Nannizziopsis vriesii* on potato dextrose agar after 2 months growth at 30 °C. Note the presence of numerous globose infertile ascomata (pseudogymnothecia) (UAMH 9665).

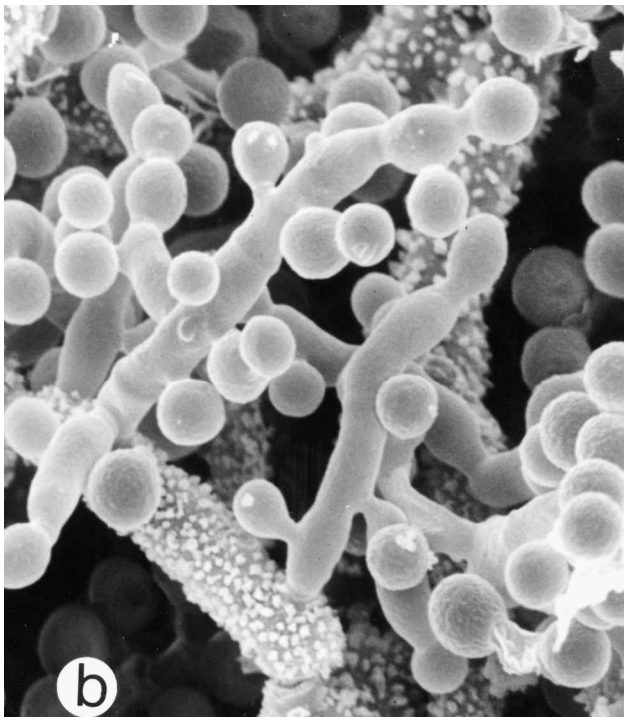



Fig. 6 A pseudogymothecium of the *Chrysosporium* anamorph of *Nannizziopsis vriesii* examined by SEM. (a) A cluster of globose conidia among asperulate hyphae (UAMH 9665). Scale bar, 7 μ m; (b) globose conidia formed sessile (on the sides of the hyphae) or on swollen cells (9665). Scale bar, 3 μ m.

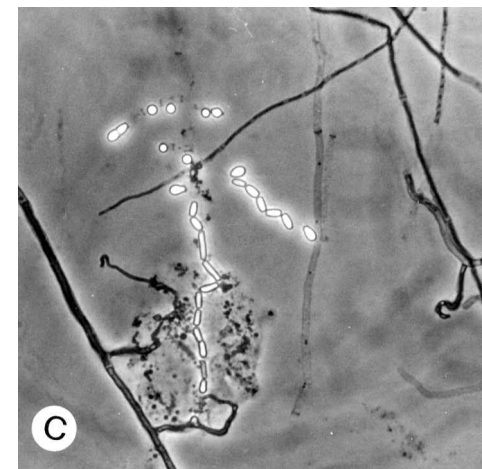
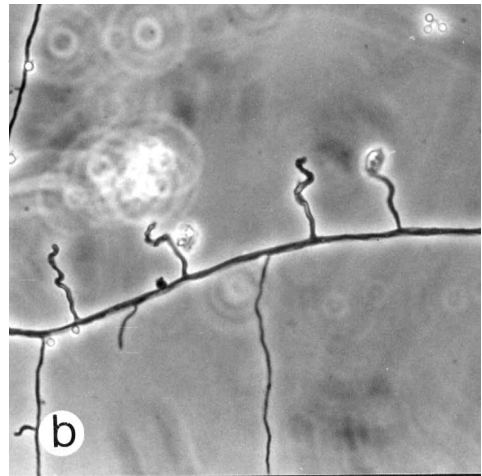
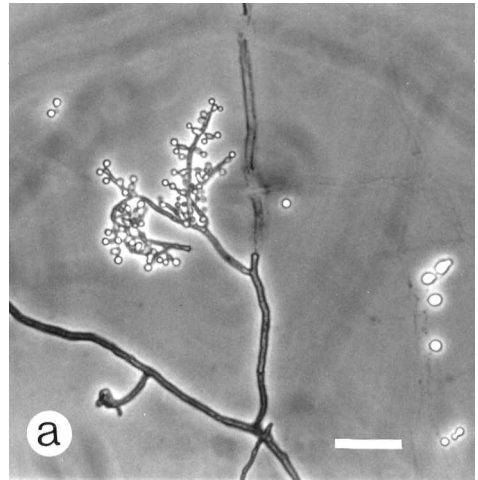


Fig. 7 The *Chrysosporium* anamorph of *Nannizziopsis vriesii* in slide culture preparations examined by light microscopy. (a) Globose to pyriform aleurioconidia formed on branched hyphae (UAMH 9664). (b) lateral undulate hyphae (9665). (c) division of hyphae into arthroconidia (9664). Scale bar, 20 μ m.

at the increased rate of 0.013% twice per day. The healed patches on the survivors remained of a darker hue for some time and then faded to the normal coloration of the skin.

After the second outbreak, the same disinfection routine was used as for the first outbreak. However, because of the secondary infections with *Aeromonas hydrophila*, one dose of neomycin at 0.2 ml per 100 g crocodile followed the next day and then 5 days later with 0.25 ml per 100 g crocodile of long-acting tetracycline were also required to eliminate the problem.

Case 2

Although the farm had been notified after the first outbreak of the successful use of Betadine and formalin to minimize the number of deaths due to this fungus, no treatment was attempted during the period of time that deaths were occurring.

Discussion

Fungi are common inhabitants of soil and can cause opportunistic diseases in reptiles [1–5,8,9,11,12,22]. Fungi can enter through wounds, cuts and abrasions and are a particular problem during the first stages of growth from the egg [23]. Some can easily pass across the egg membrane just after the egg is laid, causing death or malformations of the embryos [24–26]. Trapping, handling, temperature changes, overcrowding and transport are just some of the stressors of reptiles that can allow opportunistic pathogens to cause disease [8,22]. Because different environmental organisms can be cultured from skin and tissues of reptiles with infections, it can be difficult to establish the cause of infection.

There are several pieces of evidence to suggest that the *Chrysosporium* anamorph of *Nannizziopsis vriesii* was involved in this disease outbreak. This fungus was the only organism associated with all animals with plaque-like skin lesions and it was not isolated from any hatchling in which these lesions were not observed. The histopathology showed hyaline, septate, branched hyphae that infiltrated into the epidermis and occasionally into the dermis and hypodermis layers in all infected animals. Although these hyphae could not be distinguished from those of *Fusarium* or *Paecilomyces* species, the presence of arthroconidia (Fig. 2) has been reported previously in infections involving this *Chrysosporium* species [19]. The two other fungi that were found to be commonly present on the backs of the hatchlings in the tanks – *F. solani* and *P. lilacinus* – were also found on the backs of hatchlings in other tanks where the infection did not occur. These fungi were isolated also from crocodiles

in the infected tank that did not show signs of lesions either visually or by histopathology. *F. solani* and *P. lilacinus* are common contaminants in the warm, humid environment of crocodile pens [5] and are especially evident in situations where meat and chicken heads are used as a food source. Fat from the food lays on the water and floor of the tank and transfers to the crocodile, thus leaving a covering layer of material suitable for the growth of the fungi.

Nannizziopsis vriesii is an ascomycetous fungus classified in the order Onygenales, family Onygenaceae [27,28]. The species was described originally for an isolate obtained from skin and lungs of a lizard and is represented currently only by one other isolate from soil in California [27,29]. Both isolates produce the teleomorph when grown on sporulation media at the optimum temperature of 30 °C [7]. The gymnothecia composed of branched asperulate hyphae are indistinguishable from the pseudogymnothecia produced by the crocodile isolates except that they contain globose ascospores rather than masses of conidia. Additionally, *N. vriesii* demonstrates a *Chrysosporium* anamorph, with growth habit and physiological profile similar to that of the fungus described here from infected crocodiles, and from skin and deep infection in chameleons [7] and brown tree snakes [19]. It is not uncommon for heterothallic onygenalean fungi to form pseudogymnothecia in the absence of a compatible mating partner [6,27] but matings among reptile isolates have failed, thus far, to yield ascomata *in vitro* (this study, unpublished results). Sexual reproduction in fungi is influenced by both genetic (requiring compatible mating partners among heterothallic species) and physical parameters (culture conditions, medium constituents, temperature, light, etc.). The conditions required for development of the teleomorph among this group of reptile isolates are still being investigated. In absence of the teleomorph, it is difficult to confirm their identification as *N. vriesii*. For this reason, we are using the anamorphic name pending further investigation of relationship using molecular methods.

The source of the outbreaks is not clear. The infection occurred on two separate occasions during the first case. The first outbreak was restricted to one clutch: clutch 89. It is possible that the fungus occurred in the soil of the nesting material and contaminated the eggs as they were being laid. Whether the hatchlings were infected by the fungus crossing the egg membrane, as has occurred with *Fusarium* species in reptiles [3,23], or as they discarded their shell, is not known. As there were no isolations of the fungus from internal organs of the crocodiles, the latter premise is more likely. Transport of the 2-day-old hatchlings to OVL may have triggered the infection.

However, in the first case, the electrical failure and the resulting drop in temperature is likely to have exacerbated the problem. The treatment regime of Betadine on the deplaqued areas followed by formalin treatment in the water overcame the problem in this clutch and none of the surviving members of clutch 89 relapsed during the remainder of the trial.

The second outbreak (involving crocodiles from clutches 96, 99 and 102) was more severe and occurred in one of the two tanks in the trial held at the lowest water temperature of 26 °C. Fungal infections can be triggered by lower than ideal temperatures and in these cases they often involve the skin [30]. Of the 11 animals submitted for culture from this tank, only five showed lesions compatible with those observed in the first outbreak. The low-temperature stress here was enough to also allow a bacterial septicaemia due to *A. hydrophila* to cause some of the deaths. Since the second outbreak occurred in a different tank to the first outbreak and also with crocodiles from different clutches than the first, it is interesting to speculate on the origin of the infection. Only animals in clutches 96 (1/5) and 99 (4/5) were infected and these animals were transported down to OVL with clutch 89. Clutch 102 that had animals dying from bacterial septicaemia was transported at a later time. The crocodiles in the remaining tank held at a water temperature of 26 °C were from clutches 89, 90 and 103 and showed no signs of fungal disease during the trial.

Because the nesting data for the farm was unavailable for the 1994 season, it is impossible to say whether nests 89, 96, 99 and 102 were situated close together and/or had a similar nest composition. The eggs from nests 96 and 99 may have come in contact with the fungus in the soil but it is more likely the hatchlings were infected during transport with the hatchlings from clutch 89.

In the second case, it was impossible to determine to which clutch an infected crocodile belonged because hatchlings from five clutches had been penned together during the outbreak. The individual crocodiles were not identified to clutch.

One common feature between the 1994 and 1997 outbreaks was that all the affected clutches were laid in February and hatched in May. The optimal growth of the *Chrysosporium* anamorph of *N. vriesii* is 30 °C with a maximum near 37 °C [7,19, this study]. February is one of the hottest and most humid of months in northern Queensland and therefore the conditions at lay could predispose for growth of the fungus.

The *Chrysosporium* anamorph of *Nannizziopsis vriesii* has not been reported previously from Australia. However, an unidentified *Chrysosporium* species has been reported from Australia from scales of two lizard

species (*Varanus* sp. and *Egernia bungana*) [16] and a high prevalence of *Chrysosporium* species has been recorded from hairs of animals without lesions [16] and from feathers of domestic and wild birds [17,18], accounting for 11.1% of fungi isolated from mammals and reptiles, 21.8% of fungi from native birds and 84.8% of fungi from domestic birds [18]. However, none of these animals or reptiles showed signs of infection. *Chrysosporium* species have also been isolated frequently from soils in Queensland and Papua New Guinea, especially in animal pastures and areas used by birds [15,18]. In an attempt to ascertain the environmental source of the *Chrysosporium* from the present outbreak, cultures were obtained from crocodile nests from three farms in northern Queensland, as well from shells of two crocodile eggs from different farms. These samples grew *Chrysosporium indicum* (unpublished results) [6].

It has been suggested that the *Chrysosporium* anamorph of *N. vriesii* can readily infect reptilian tissues [7,19]. This could occur through cuts and scratches especially at times of stress. We suggest that the stress of handling and transport of the hatchlings to the laboratory followed by an electrical failure resulting in a marked drop in the water temperature led to infection with this fungus in the first case. Crocodiles in captivity tend to collect as a group under 'hide boards' and can stack two to four deep. This is an ideal situation to allow for the transmission of the arthroconidia that may be erumpent through the epidermis of infected animals (Fig. 2). Overcrowding and environmental factors may have contributed to the second outbreak. As well the fungus appears to be persistent in the environment of these farmed animals as evidenced by a recent case observed while this manuscript was in review. Two of six hatchlings sent from the same farm died on route to OVL and were examined by culture and histopathology. The *Chrysosporium* anamorph of *N. vriesii* was isolated in pure culture from skin plaques of one of these animals and hyphae were observed in the necrotic epidermis.

Acknowledgements

The authors wish to thank R. Jack for his dedication in looking after the crocodiles, L. Kulpa for histology techniques, M. Chen for assistance with scanning electron microscopy, and A. Flis for technical assistance. Funding for this work came from the Rural and Industrial Research and Development Council, Australia, and from grants from the Natural Sciences and Engineering Research Council of Canada and the University of Alberta Small Faculties Fund.

References

- 1 Jacobson ER, Cheatwood JL, Maxwell LK. Mycotic diseases of reptiles. *Sem Avian Exotic Pet Med* 2000; **9**: 94–101.
- 2 Maslen M, Whitehead J, Forsyth WM, McCracken H, Hocking AD. Systemic mycotic disease of captive crocodile hatchling (*Crocodylus porosus*) caused by *Paecilomyces lilacinus*. *J Med Vet Mycol* 1988; **26**: 219–225.
- 3 Hibberd EMA, Harrower KM. Mycoses in crocodiles. *The Mycologist* 1993; **7**: 32–37.
- 4 Buenviaje GN, Ladds PW, Melville L, Manolis SC. Disease-husbandry associations in farmed crocodiles in Queensland and the Northern Territory. *Aust Vet J* 1994; **6**: 165–173.
- 5 Buenviaje GN, Ladds PW, Martin Y. Pathology of skin diseases in crocodiles. *Aust Vet J* 1998; **76**: 357–363.
- 6 Kane J, Summerbell RC, Sigler L, Krajden S, Land G. *Laboratory Handbook of Dermatophytes*. Belmont, California: Star, 1997.
- 7 Paré JA, Sigler L, Hunter DB, Summerbell RC, Smith DA, Machin KL. Cutaneous mycoses in chameleons caused by the *Chrysosporium* anamorph of *Nannizziopsis vriesii* (Apinis) Currah. *J Zoo Wildlife Med* 1997; **28**: 443–453.
- 8 Austwick PKC, Keymer IF. Fungi and actinomycetes. In: Cooper JE, Jackson OF, eds. *Diseases of the Reptilia*. New York: Academic Press, 1981: 193–231.
- 9 Frye FL. *Biomedical and Surgical Aspects of Captive Reptile Husbandry*. Edwardsville, Kansas: Veterinary Medicine, 1981.
- 10 Hazell SL, Eamens GJ, Perry RA. Progressive digital necrosis in the eastern blue-tongued skink, *Tiliqua scincoides* (Shaw). *J Wildl Dis* 1985; **21**: 186–188.
- 11 Schildger BJ, Frank H, Gobel T, Weiss R. Mycotic infections of the integument and inner organs in reptiles. *Herpetopathologia* 1991; **2**: 81–97.
- 12 Vissienon Th, Schuppel KF, Ullrich E, Kuijpers AFA. Case report. A disseminated infection due to *Chrysosporium queenslandicum* in a garter snake (*Thamnophis*). *Mycoses* 1999; **42**: 107–110.
- 13 Kuttin ES, Muller J, May W, Albrecht F, Sigalas M. Mykosen bei krokodilen. *Mykosen* 1978; **21**: 39–48.
- 14 Connole MD. Review of animal mycoses in Australia. *Mycopathologia* 1990; **111**: 133–164.
- 15 Frey D. Isolation of keratinophilic and other fungi from soils collected in Australia and New Guinea. *Mycologia* 1965; **57**: 202–215.
- 16 Rees RG. Keratinophilic fungi from Queensland. I. Isolations from animal hair and scales. *Sabouraudia* 1967; **5**: 165–172.
- 17 Rees RG. Keratinophilic fungi from Queensland – 2. Isolations from feathers of wild birds. *Sabouraudia* 1967; **6**: 14–18.
- 18 Rees RG. Keratinophilic fungi from Queensland – 3. Isolations from feathers of domestic fowls. *Sabouraudia* 1967; **6**: 19–28.
- 19 Nichols DK, Weyant RS, Lamirande EW, Sigler L, Mason RT. Fatal mycotic dermatitis in captive brown tree snakes (*Boiga irregularis*). *J Zoo Wildlife Med* 1999; **30**: 111–118.
- 20 Sigler L, Thomas AD. *Nannizziopsis vriesii*-like fungus causing cutaneous infection in Australian saltwater crocodiles. Los Angeles, California: American Society for Microbiology, 1999: Z-6.
- 21 Cox JM. Lysine–mannitol–glycerol agar, a medium for the isolation of *Salmonella* spp., including *S. typhi* and atypical strains. *Appl Environ Microbiol* 1993; **59**: 2602–2606.
- 22 Migaki G, Jacobson ER, Casey HW. Fungal diseases in reptiles. In: Hoff GL, Frye FL, Jacobson ER, eds. *Diseases of Amphibians and Reptiles*. New York: Plenum Press, 1984: 183–204.
- 23 Cabanes FJ, Alonso JM, Castella G, Alegre F, Domingo M, Pont S. Cutaneous hyalohyphomycosis caused by *Fusarium solani* in a loggerhead sea turtle (*Caretta caretta* L.). *J Clin Microbiol* 1997; **35**: 3343–3345.
- 24 Schumacher J, Cardeilhac PT. Mycotic infections of egg membranes in the American alligator (*Alligator mississippiensis*). *IAAAM Proc* 1990; **21**: 138–140.
- 25 Kunert J, Chmelik P, Bic V. *Fusarium solani*: invader of the ophidian eggs of *Elaphe guttata* in captivity. *Mycopathologia* 1993; **122**: 65–68.
- 26 Hibberd EMA. Fungal disease in eggs and hatchlings of farmed *Crocodylus porosus*. *The 12th Working Meeting of the IUCN Crocodile Specialist Group*, Pattaya, Thailand, 2–6 May 1994.
- 27 Currah RS. Taxonomy of the Onygenales. *Mycotaxon* 1985; **24**: 1–216.
- 28 Guarro J, Cano J, de Vroey Ch. *Nannizziopsis* (Ascomycotina) and related genera. *Mycotaxon* 1991; **42**: 193–200.
- 29 Sigler L, Flis A. *Catalogue of the University of Alberta Microfungus Collection and Herbarium*. 3rd edn. Edmonton, University of Alberta, 1988: 1–213.
- 30 Fromtling RA, Kosanke SD, Jensen JM, Bulmer GS. Fatal *Beauveria bassiana* infection in a captive American alligator. *JAVMA* 1979; **175**: 934–936.