

Case Reports

Invasive *Mycoleptodiscus* fungal cellulitis and myositis

SOPHIA KOO*†‡, DEANNA A. SUTTON§, WENDY W. YEH*†‡, ELIZABETH H. THOMPSON§, LYNNE SIGLER#, JUDY F. SHEARER^, DEBORAH E. HOFSTRA\$, BRIAN L. WICKES§ & FRANCISCO M. MARTY*†‡

*Division of Infectious Diseases, Brigham & Women's Hospital, Boston, †Dana-Farber Cancer Institute, Boston, ‡Harvard Medical School, Boston, Massachusetts, §Fungus Testing Laboratory, Department of Pathology, University of Texas Health Science Center at San Antonio, San Antonio, TX, #University of Alberta Microfungus Collection and Herbarium, Devonian Botanic Garden, Edmonton, Alberta, Canada, ^US Army Corps of Engineers, Engineer Research and Development Center, Vicksburg, Mississippi, USA, and \$National Institute of Water & Atmospheric Research, Hamilton, New Zealand

We report progressive necrotizing fungal cellulitis and myositis in the leg of a patient with glioblastoma multiforme treated with temozolomide and corticosteroids. While the morphologic appearance of the isolate and its ability to grow at temperatures greater than 32°C were suggestive of *Mycoleptodiscus indicus*, some of the conidia were atypical for this species in that they had single septa and occasional lateral appendages. Furthermore, the isolate was different from *M. indicus* based on the sequencing analysis of two rDNA regions. This is the first case of *Mycoleptodiscus* invasive fungal disease in which the causative agent could not be resolved at the species level because of inconsistencies between morphological and molecular data.

Keywords *Mycoleptodiscus*, invasive fungal disease, dematiaceous, temozolomide

Introduction

Members of the genus *Mycoleptodiscus*, currently comprising 18 species, are well-known plant pathogens, particularly in tropical and subtropical regions. For example, the type species, *Mycoleptodiscus terrestris*, was initially described as an agent of root rot in red clover and other leguminosae [1,2]. *Mycoleptodiscus indicus* is associated with leaf-spot disease of *Ixora* and other hosts in India [3,4] and has been linked with leaf necrosis in cycads [5]. In culture, *Mycoleptodiscus* species produce pale brown hyphae with abundant appressoria and irregularly-shaped sporodochial conidiomata composed of dark brown cells bearing ampulliform phialides with a single collarette [6–10]. Conidia are typically hyaline and curved, with 0–3 hair-like appendages. Conidial production is uncommon but may be stimulated by growing the organism in light and by addition of plant material to culture media [11].

Three human cases of invasive *M. indicus* skin and joint infections, all presumably initiated by direct traumatic inoculation of the fungus from plant matter, have been previously reported to date [7–9]. No other *Mycoleptodiscus* species has been described as being pathogenic to humans.

Case report

A 31-year-old man with glioblastoma multiforme (GBM) presented with a week history of progressive and severe pain, erythema, and swelling in his right ankle and dorsal surface of his foot. He denied fevers, chills, sweats, or any additional localizing symptoms.

The GBM of his right frontal lobe was diagnosed four months prior to his current illness. He underwent partial resection of the GBM and completed a course of involved-field radiation therapy plus temozolomide and dexamethasone treatment prior to his current illness. He was receiving a tapering dose of dexamethasone at the time he first noticed his lower extremity symptoms.

Past medical history was otherwise remarkable for seizures in the setting of his GBM, recent inferior vena

Received 10 October 2011; Received in final form 23 December 2011; Accepted 9 January 2012.

Correspondence: Sophia Koo, Brigham and Women's Hospital – Division of Infectious Diseases, 75 Francis Street, PBB-A4 Boston, MA 02115, USA. Tel.: +1 617 525 8418; Fax: +1 617 732 6829; E-mail: skoo@partners.org

cava filter placement for extensive pulmonary emboli, and steroid-induced diabetes mellitus. He had received temozolomide one month previously and was currently taking 6 mg of dexamethasone daily. He had been prescribed oxycodone as needed for lower extremity pain a few days prior to his current admission.

The patient had worked in road construction and cleaned sewer pipes in Massachusetts, USA. He had no pets and he denied any unusual contact exposures or prior trauma to his lower extremities.

His temperature was 37.7°C, heart rate 120 beats per minute, and blood pressure 150/96 mmHg. He was abulic and slow to respond to questions. His physical examination demonstrated marked pitting edema throughout his right lower extremity, with diffuse erythema and warmth of the dorsal surface of his right foot and the anterior and lateral surfaces of his right ankle, as well as a hematoma on his right dorsolateral foot with tense, slightly dusky overlying skin. These erythematous areas were exquisitely tender to palpation. There were no areas of disrupted skin integrity or tinea pedis. Pulses were normal in both lower extremities. Laboratory values were notable for a leukocyte count of 9,210 cells/ μ l with 62% neutrophils and 9% bands.

The patient initially received vancomycin for empiric treatment of severe cellulitis and enoxaparin for a popliteal deep vein thrombosis diagnosed on ultrasound. His pain became increasingly severe over the next day, and he required high narcotic doses for pain control. Ceftazidime and clindamycin were added to his empiric antimicrobial regimen but despite these measures, his right distal calf, ankle, and foot became increasingly erythematous, mottled, and swollen. The area of hematoma on his right foot spontaneously opened and drained copious serosanguinous material.

Three days after his initial presentation, pressures in each of the compartments of his increasingly swollen right leg were elevated between 30 and 60 mmHg, which required surgical decompression. During his four-compartment fasciotomy, purulent-appearing material with hematoma was noted in his superficial posterior compartment and a large hematoma superficial to the medial and lateral heads of his gastrocnemius muscle. Non-viable skin and tissue on the dorsal surface of his right foot was debrided to the intrinsic muscles of his foot, and necrotic material between the third and fourth interspaces of his foot was removed. The hematoma on the dorsolateral aspects of the right foot was evacuated and debrided the wound was copiously irrigated.

Examination of a piece of tissue from the medial head of the gastrocnemius muscle which had been sent to pathology for intraoperative frozen section review revealed acute inflammation and necrosis of his skeletal muscle and invasive hyphal elements. He received liposomal amphotericin

5 mg/kg IV daily postoperatively. He returned to the operating room the following day for inspection of his lower extremity wound. His muscles appeared inflamed and edematous, and a pocket of cloudy fluid between the gastrocnemius and soleus muscles was drained.

Final pathologic examination with Gomori methenamine silver staining of the calf muscle specimen from his first debridement confirmed the presence of abundant invasive septate, parallel-walled or irregularly swollen hyphae in the setting of acute inflammation and tissue necrosis (Fig. 1).

Specimens of four anatomically distinct areas from his original fasciotomy and debridement were sent for culture. Gram stains of all specimens showed rare polymorphonuclear cells but no microorganisms. Cultures on Sabouraud dextrose agar slants incubated at 25°C in darkness all grew a similar appearing mold within 48 h. The isolates were subcultured to potato dextrose agar (PDA) and incubated at 25°C to stimulate conidial formation. The mold was macroscopically yellowish and gray in appearance with a black reverse. Microscopic studies demonstrated hyphae which appeared septate and many darkly pigmented appressoria, but no conidia were seen. This isolate was submitted to the Fungus Testing Laboratory at the University of Texas Health Science Center in San Antonio for further identification and antifungal drug susceptibility testing. Fungal isolator cultures of blood samples were negative. Serum beta-glucan was >500 pg/ml and serum galactomannan index 0.10.

Given the isolation of a dematiaceous mold, amphotericin was discontinued and voriconazole was started at a dose of 200 mg orally three times daily [12]. The appearance of the patient's lower extremity initially improved, with decreasing erythema and swelling. Three weeks after the patient's initial debridement, he developed fevers of up

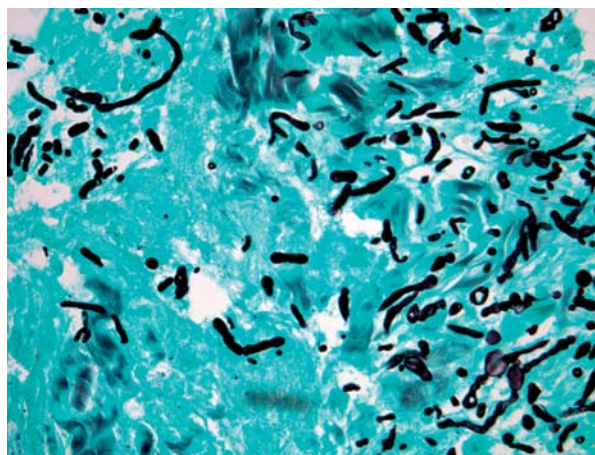


Fig. 1 Gomori methenamine silver stain of the patient's calf muscle biopsy specimen, showing abundant hyphal elements and necrotic tissue.

to 38.2°C and new areas of ulceration and erythema in his right forefoot and prominent swelling in his medial calf despite voriconazole therapy. He returned to the operating room for an examination of his leg under anesthesia, and was found to have edematous muscle and pockets of cloudy, purulent fluid in the medial aspect of his wound. The majority of his gastrocnemius muscle appeared nonviable, and extensive areas of necrotic muscle were debrided. Pathologic examination of material from his deep calf tissue showed numerous invasive fungal forms associated with necroinflammatory debris and fibrin, acute and chronic inflammation, and abscess formation. Examination of debrided tissue from his right forefoot showed ulceration and acute and chronic inflammation in association with fungal hyphae. This specimen was unfortunately not sent for culture.

Given his lack of clinical improvement over the following week and the questionable functionality of his remaining leg with attempted limb salvage through further debridement procedures, he underwent amputation of his leg approximately one month after his initial presentation. A large collection of purulent material was discovered in the posterior compartment of his leg adjacent to his knee, and his leg was therefore amputated just proximal to the knee. The margin of his resection specimen appeared viable, without any evidence of involvement by his infection.

Voriconazole was discontinued three weeks after his amputation and he had no further recurrence of his invasive fungal infection. Unfortunately, the patient passed away from progressive GBM disease approximately one year after his amputation procedure. At the Fungus Testing Laboratory, the isolate was accessioned as UTHSC 08-1754 (= R-4426) and subcultured onto potato flake agar (PFA), carnation leaf agar, and V-8 juice agar, all prepared in-house, and incubated at 25°C. On PFA, colonies were moderately fast growing, initially light gray, becoming a darker gray with a black reverse and a yellow pigment. Abundant appressoria suggested a possible *Mycoleptodiscus* species (Fig. 2a) and these were compared with those described for various species in this genus [6].

However, since appressorial features are quite similar among different *Mycoleptodiscus* species, these structures are not very useful for identification of our isolate. Similar appressoria are also seen in the more common coelomycetous genus, *Colletotrichum*, but *Colletotrichum* species were ruled out upon observations of conidia. The most useful medium for the formation of diagnostically useful structures was V-8 juice agar, what with the development of conidiomata, conidiogenous cells and conidia after 5 days incubation. Conidiogenous cells were broadly ovate or ampulliform with a prominent aperture and flared collarette (Fig. 2b). Conidia were hyaline and mostly aseptate (Fig. 2b), although rare conidia contained a single septum

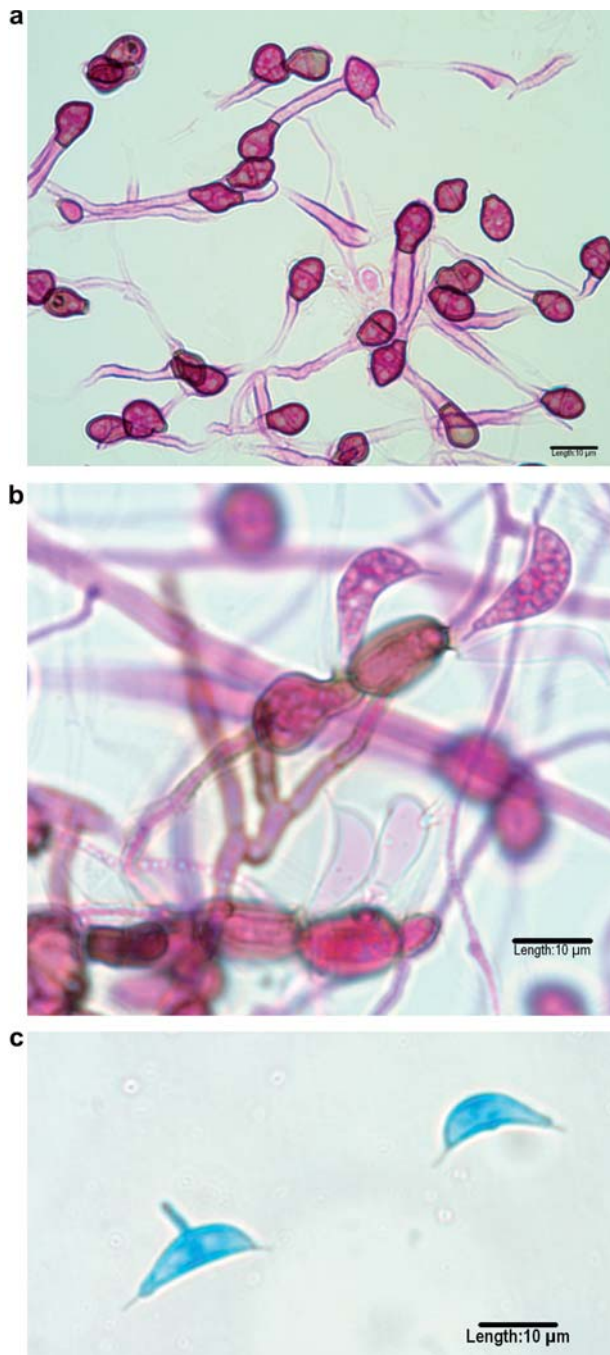


Fig. 2 (a) Appressoria in lacto-fuchsin mounting medium produced in a PFA slide culture after 5 days incubation at 25°C. (b) Conidiogenous cells with collarettes and aseptate conidia with polar appendages. Tease mount from V-8 juice agar in lacto-fuchsin mounting medium. (c) Conidium with a lateral appendage. Tape mount from V-8 juice agar in lactophenol cotton blue.

and displayed polar and occasionally, lateral appendages (Fig. 2c). Based on these morphologic features, the isolate was identified as a *Mycoleptodiscus* species [7–10]. While the phenotypic morphology of the isolate was suggestive

of *M. indicus*, the conidial features, including occasional septa and lateral appendages, were somewhat atypical for this species. We sequenced the internal transcribed spacer (ITS) region and the D1/D2 region of the large subunit of the nuclear rRNA gene of this isolate, under accession number UTHSC R-4426, for more definitive species identification. DNA was obtained from an isolate grown on PDA at 30°C for 20 h. ITS amplicons were obtained using ITS1 and ITS4 primers [14] and D1/D2 amplicons were attained with primers NL1 and NL4 through the use of previously described PCR conditions [10,15,16]. Purified templates were sequenced in both directions at the Advanced Nucleic Acids Core Facility at the University of Texas Health Science Center at San Antonio using the same primers for ITS and D1/D2 amplification.

ITS and D1/D2 sequences were compared to available sequences in the National Center for Biotechnology Information nucleotide database (<http://www.ncbi.nlm.nih.gov/blast/Blast.cgi>). Using a query length of $\geq 90\%$ and percent identity of $\geq 97\%$ as cut-offs for significance, the closest matches of the ITS search were *M. terrestris* [GenBank# U97332, Identity = 615/615 (100%)] and *M. terrestris* [EU364807, Identity = 559/576 (97%)]. Despite our isolate's phenotypic resemblance to *M. indicus*, there was relatively low ITS similarity (78–81% identity) with available *M. indicus* sequences from clinical isolates (GU220382 [10], GU980698, GU980694 and GU980696 [8]). Similarly, a BLAST search with the D1/D2 sequence was only 92% similar to sequences of *M. indicus* derived from the same set of clinical isolates (GU220383, GU980693, GU980695, GU980697 [8]). There were no D1/D2 sequences for *M. terrestris* in GenBank.

Because the morphology of the isolate appeared inconsistent with the sequence results, we sought to obtain corresponding sequences from ex-type cultures of *M. terrestris* and *M. indicus*. The ex-type culture of *M. terrestris* was acquired from the Centraalbureau voor Schimmelcultures (Utrecht, The Netherlands) as CBS 231.53 and sequenced under our reference number R-4537. *M. indicus* is represented by a dried type specimen IMI 108220 (CABI Biosciences, Kew, UK [4]) but there is no living culture. An inquiry about the availability of material for loan and DNA extraction determined that the specimen consists of only two small leaves and that the material would be insufficient for analysis (P. Cannon, personal communication to LS). Pair-wise comparison using Sequencher (Gene Codes Corp., Ann Arbor, MI, USA) confirmed that the ITS sequence from the case isolate was 100% (515/515 bp) similar to GenBank U97332 and 98.3% (506/515 bp) similar to the type R-4537 of *M. terrestris*, both derived from United States isolates. A third isolate of Chinese origin (EU36487) was 96.5% (503/521 bp) similar. No sequences from other *Mycocleptodiscus* species were available for

comparative analysis. Comparison of the D1/D2 sequences revealed greater divergence with only 92.5% (570/616 bp) similarity between the case isolate and the *M. terrestris* type strain.

The case isolate was deposited in the University of Alberta Microfungus Collection and Herbarium, Edmonton, Alberta, Canada, under accession number UAMH 11158 (= R-4426). The D1/D2 and ITS sequences of R-4426 were deposited into GenBank under accession numbers JN654989 and JN654999, respectively. D1/D2 and ITS sequences of R-4537 were deposited under accession numbers JN711859 and JN711860, respectively. Since *M. terrestris* is reported to be unable to grow at temperatures higher than 32°C, we conducted maximum temperature of growth studies [17]. Our isolate demonstrated excellent growth after 7 days of incubation on PFA slants at 25, 30, 35 and 40°C. The strain appeared to grow optimally at 30°C, and no growth was observed at 45 or 50°C.

Antifungal drug susceptibility testing was performed according to the method outlined in Clinical and Laboratory Standards Institute (CLSI)-approved standard M38-A2 [13]. Maximum inhibition was obtained after 48 h at 0.5 µg/ml, 0.06 µg/ml, 0.03 µg/ml, and 0.25 µg/ml of voriconazole, posaconazole, terbinafine, and amphotericin B, respectively. Although no defined breakpoints exist for this organism, results would suggest susceptibility to all agents based upon achievable drug concentrations using standard dosing regimens.

Discussion

All three human cases of invasive *M. indicus* skin and joint infections reported to date were resolved by either debridement or a relatively brief course of systemic antifungal therapy. The first patient was an avid gardener from South Carolina with Wegener's granulomatosis who was treated with methotrexate and corticosteroids and developed *M. indicus* prepatellar bursitis and synovitis after gardening on his bare knees [7]. He underwent multiple debridements of his knee and received an 18-day course of amphotericin B, then a month of itraconazole with resolution of his infection. The second patient was a liver transplant recipient from Florida with HIV and hepatitis C co-infections. He developed numerous subcutaneous nodules in a sporotrichoid distribution on his hand shortly after receipt of pulsed corticosteroids for acute allograft rejection. This individual developed these lesions while taken care of *Zamia* cycads [9]. He received liposomal amphotericin, then oral voriconazole 200 mg twice daily. When his skin lesions did not improve after 4 weeks of antifungal treatment, he received granulocyte-macrophage colony-stimulating factor and his voriconazole dose was

increased to 300 mg twice daily. He received voriconazole at this dose for 4 months with full resolution of his skin lesions. The third patient developed *M. indicus* synovitis and osteomyelitis in the absence of any apparent immunocompromising conditions, after being scratched by the sharp leaves of tropical plants while vacationing in Costa Rica [8]. His infection resolved with simple debridement of affected areas of bone and synovial tissue without receiving any antifungal therapy. Two other potential cases of human *M. indicus* cutaneous infections were mentioned in the same report, but few details of the clinical history were available [8]. *M. indicus* has also caused progressive subcutaneous infection and lymphadenitis, then systemic dissemination, in an immunocompromised dog [10].

The origin of our patient's invasive *Mycocleptodiscus* infection remains unclear. Although he had worked in road construction and cleaned sewer pipes prior to his illness, he had not engaged in these activities for several months prior to his current presentation and he denied a previous history involving penetrating trauma to his leg. Invasive fungal infections have been described years after penetrating injury as a result of contact with plant matter, in the setting of immunosuppression [18].

It is also unclear why this patient's clinical course was substantially more fulminant than described in other *Mycocleptodiscus* infections despite aggressive debridement and active antifungal therapy with amphotericin and voriconazole. Perhaps his immunosuppression was more profound, with temozolomide and corticosteroid treatment, his infection was more extensive at the time of presentation, or his particular *Mycocleptodiscus* strain was more virulent than the etiologic *M. indicus* strains in the earlier reports. Temozolomide chemotherapy, especially in patients concurrently receiving corticosteroids, is known to cause marked CD4 lymphopenia [19–21] and is associated with a wide array of opportunistic infections, including cytomegalovirus infection [20,22], *Pneumocystis jirovecii* pneumonia [19,20,23,24], cryptococcal meningitis [25], and invasive aspergillosis [19,26].

This case of invasive *Mycocleptodiscus* infection is the first in which identification of the isolate could not be resolved at the species level because of dissimilarities between morphological and molecular results. Identification was especially challenging given the limited number of *Mycocleptodiscus* isolates available for comparative morphological and molecular analysis. The morphologic appearance of our isolate and its growth at temperatures greater than 32°C were suggestive of *M. indicus* [11]. The D1/D2 sequence was equally dissimilar with *M. indicus* clinical isolates and the *M. terrestris* type isolate, and the ITS sequence aligned more closely with *M. terrestris* isolates. The contrasting morphological, D1/D2 and ITS sequence results indicated unresolved taxonomic

relationships within *Mycocleptodiscus*. Morphological and preliminary ITS assessment performed by two authors of this report (JS, DH) demonstrates a high level of variation among isolates identified as *M. terrestris*. On this basis, it is reasonable to postulate that a similarly high level of variation exists amongst isolates of other *Mycocleptodiscus* species. The isolate obtained from this patient may be representative of the diversity among *Mycocleptodiscus* species or it may represent a different species. Further taxonomic clarification and a greater understanding of the diversity within the *Mycocleptodiscus* genus will be an ongoing endeavor and require the assembly of further representative cultures of each of the known species.

Declaration of interest: The authors report no conflicts of interest. The authors alone are responsible for the content and writing of the paper.

References

- 1 Gerdemann JW. An undescribed fungus causing a root rot of red clover and other Leguminosae. *Mycologia* 1953; **45**: 548–554.
- 2 Ostazeski SA. An undescribed fungus associated with a root and crown rot of birdsfoot trefoil (*Lotus corniculatus*). *Mycologia* 1967; **59**: 971–975.
- 3 Sahni V. Deuteromycetes from Jabalpur. III. *Mycopath Mycol Appl* 1965; **36**: 267–288.
- 4 Sutton BC. *Pucciniopsis*, *Mycocleptodiscus* and *Amerodiscoiella*. *Trans Br Mycol Soc* 1973; **60**: 525–536.
- 5 El-Gholl NE, Alfieri SA. Leaf necrosis of *Zamia* caused by *Mycocleptodiscus indicus*. *Plant Pathology Circular* 1991; **349**.
- 6 Alcorn J. Appressoria in *Mycocleptodiscus* species. *Aust Syst Bot* 1994; **7**: 591–603.
- 7 Padhye AA, Davis MS, Reddick A, et al. *Mycocleptodiscus indicus*: a new etiologic agent of phaeohyphomycosis. *J Clin Microbiol* 1995; **33**: 2796–2797.
- 8 Metry CA, Hoiem-Dalen PS, Maddox CW, et al. Subcutaneous *Mycocleptodiscus indicus* infection in an immunosuppressed dog. *J Clin Microbiol* 2010; **48**: 3008–3011.
- 9 Dewar CL, Sigler L. Fungal arthritis of the knee caused by *Mycocleptodiscus indicus*. *Clin Rheumatol* 2010; **29**: 1061–1065.
- 10 Garrison AP, Procop GW, Vincek V, et al. A case of subcutaneous *Mycocleptodiscus indicus* infection in a liver transplant recipient successfully treated with antifungal therapy. *Transpl Infect Dis* 2008; **10**: 218–220.
- 11 Shearer JF. Some observations concerning microsclerotia and spore production of *Mycocleptodiscus terrestris* in culture. *Mycologia* 2007; **99**: 88–90.
- 12 Revankar SG. Phaeohyphomycosis. *Infect Dis Clin North Am* 2006; **20**: 609–620.
- 13 Clinical and Laboratory Standards Institute. *Reference Method for Broth Dilution Antifungal Susceptibility Testing of Filamentous Fungi*. Approved standard M38-A2. Wayne, PA: Clinical and Laboratory Standards Institute, 2009.
- 14 White TJ, Bruns TD, Lee SB, Taylor JW. Amplification and sequencing of fungal ribosomal RNA genes for phylogenetics. In: Innis N, Gelfand D, Sninsky J, White TC (eds). *PCR-Protocols and Applications: A Laboratory Manual*. New York, NY: Academic Press; 1990: 315–322.

- 15 Kurtzman CP, Robnett CJ. Identification of clinically important ascomycetous yeasts based on nucleotide divergence in the 5' end of the large-subunit (26S) ribosomal DNA gene. *J Clin Microbiol* 1997; **35**: 1216–1223.
- 16 Peterson SW, Kurtzman CP. Phylogenetic relationships among species of the genus *Issatchenkia* Kudriavzev. *Antonie van Leeuwenhoek* 1990; **58**: 235–240.
- 17 Jackson M, Dunlap C, Shearer J, Heilman M, Palmquist D. The impact of temperature on the production and fitness of microsclerotia of the fungal bioherbicide *Mycocleptodiscus terrestris*. *Biocontrol Sci Techn* 2011; **21**: 547–562.
- 18 Marty FM, Petschnigg EM, Hammond SP, *et al*. Invasive fungal disease after remote inoculation in transplant recipients. *Clin Infect Dis* 2011; **52**: e7–10.
- 19 Su YB, Sohn S, Krown SE, *et al*. Selective CD4 + lymphopenia in melanoma patients treated with temozolomide: a toxicity with therapeutic implications. *J Clin Oncol* 2004; **22**: 610–616.
- 20 Schwarzberg AB, Stover EH, Sengupta T, *et al*. Selective lymphopenia and opportunistic infections in neuroendocrine tumor patients receiving temozolomide. *Cancer Invest* 2007; **25**: 249–255.
- 21 Rietschel P, Wolchok JD, Krown S, *et al*. Phase II study of extended-dose temozolomide in patients with melanoma. *J Clin Oncol* 2008; **26**: 2299–2304.
- 22 Meije Y, Lizasoain M, Garcia-Reyne A, *et al*. Emergence of cytomegalovirus disease in patients receiving temozolomide: report of two cases and literature review. *Clin Infect Dis* 2010; **50**: e73–76.
- 23 Stupp R, Dietrich PY, Ostermann Kraljevic S, *et al*. Promising survival for patients with newly diagnosed glioblastoma multiforme treated with concomitant radiation plus temozolomide followed by adjuvant temozolomide. *J Clin Oncol* 2002; **20**: 1375–1382.
- 24 Yu SK, Chalmers AJ. Patients receiving standard-dose temozolomide therapy are at risk of *Pneumocystis carinii* pneumonia. *Clin Oncol (R Coll Radiol)* 2007; **19**: 631–632.
- 25 Choi JD, Powers CJ, Vredenburgh JJ, Friedman AH, Sampson JH. Cryptococcal meningitis in patients with glioma: a report of two cases. *J Neurooncol* 2008; **89**: 51–53.
- 26 Damek DM, Lillehei KO, Kleinschmidt-DeMasters BK. *Aspergillus terreus* brain abscess mimicking tumor progression in a patient with treated glioblastoma multiforme. *Clin Neuropathol* 2008; **27**: 400–407.

This paper was first published online on Early Online on 15 February 2012.