

Invasive *Myceliophthora thermophila* infection mimicking invasive aspergillosis in a neutropenic patient: a new cause of cross-reactivity with the *Aspergillus* galactomannan serum antigen assay

FLORENT MORIO*†, FRANÇOIS FRAISSINET*, THOMAS GASTINNE‡, PATRICE LE PAPE*†, JACQUES DELAUNAY‡, LYNNE SIGLER§, CONNIE FE C. GIBAS§ & MICHEL MIEGEVILLE*†

*Laboratoire de Parasitologie-Mycologie, CHU de Nantes, Nantes, France, †Département de Parasitologie et Mycologie Médicale, Université de Nantes, Nantes Atlantique Universités, EA1155 IICiMed, Faculté de Pharmacie, Nantes, France,

‡Service d'Hématologie Clinique, CHU de Nantes, Nantes, France, and §University of Alberta Microfungus Collection and Herbarium, Devonian Botanic Garden, Edmonton, Alberta, Canada

Myceliophthora thermophila is a thermophilic mould widely found in the environment but rarely responsible for human infections. We describe a case of invasive *Myceliophthora thermophila* infection mimicking invasive aspergillosis in a neutropenic patient with haematological malignancy. Cross-reactivity with *Aspergillus* galactomannan assay (GM) was demonstrated by repeated positive results and confirmed by cross-reaction between the fungal isolate and the GM assay. The patient was successfully treated with voriconazole. Potential GM cross-reactivity must be considered in future studies including patients categorized as having probable invasive aspergillosis using the GM as the only mycological criterion.

Keywords invasive aspergillosis, *Myceliophthora thermophila*, galactomannan antigen assay, cross-reactivity, haematological malignancy

Introduction

Aspergillus galactomannan antigen assay (GM) has been a major advance for managing patients at risk for invasive aspergillosis (IA) especially those with haematological malignancy [1]. Because of its sensitivity and specificity, GM assay was included several years ago by the EORTC/MSG as a mycological criterion to define invasive aspergillosis. More recently, a single positive GM, associated with clinical and host criteria, was defined as sufficient for the diagnosis of probable IA [2]. However, *in vitro* cross-reactions (sometimes referred to as false-positivity) with a large number of fungi have been reported in the literature and include yeasts (such as *Geotrichum capitatum* or

Trichosporon species), dimorphic fungi and to a lesser extent moulds [3–8]. According to a recent report, cross-reaction could also occur in cases of zygomycosis but this warrants further investigations as the results are not supported by previous findings for zygomycetes in the literature [8,9]. We described the case of a neutropenic patient presenting with an acute myeloid leukaemia (AML) who was thought to have developed probable IA due to positive results in the GM assay in accord with the EORTC/MSG criteria. However, the etiologic agent was subsequently identified as the rare thermophilic mould *Myceliophthora thermophila* which was found experimentally to cross react in the *Aspergillus* galactomannan assay. The patient was successfully treated with voriconazole.

Case report

A 52-year-old man was admitted to the haematology department for treatment of AML FAB2, with an unfavourable prognosis due to multilineage dysplasia, hyperleukocytosis and abnormal karyotype (t(1;11) and 17p deletion). The

Received 23 December 2010; Received in final revised form 15 March 2011; Accepted 24 April 2011

Correspondence: Florent Morio, Laboratoire de Parasitologie-Mycologie, CHU de Nantes, Hôtel Dieu, 9 Quai Moncousu, 44093 Nantes Cedex 1, France. Tel: +332 4 008 4079; Fax: +332 4 008 4249; E-mail: florent.morio@chu-nantes.fr

initial treatment consisted of two induction regimens (daunorubicin with aracytin followed by mithoxantrone, aracytin and gemtuzumab ozogamicin). Complete haematological remission was achieved and was followed by consolidation therapy with mithoxantrone and aracytin. During aplasia and because the patient presented with fever despite broad-spectrum antibacterial therapy, empiric antifungal therapy with caspofungin was initiated (70 mg/day as a loading dose followed by 50 mg/day). Positive results with the GM (Platelia *Aspergillus*, Biorad, Marnes la Coquette, France) assay was noted on the 8th consecutive day of aplasia (index 0.97; cut-off value: 0.5) despite the absences of any respiratory symptoms. On the 11th day of aplasia, the patient developed dyspnea, chest pain and moderate hemoptysis. The day after, GM increased to 4.4, and a computed chest tomography scan revealed a large, 35 mm-diameter, subpleural nodule with a halo sign in the upper left pulmonary lobe (Fig. 1). In light of this probable IA, according to the EORTC/MSG criteria, the patient was given voriconazole (400 mg/day IV) and caspofungin was withdrawn. A bronchoalveolar lavage fluid (BAL) was sent to the laboratory for microbiological investigations. Serial samples during the hospitalization period were found to be GM positive. Four days later, cultures of the BAL specimen on Sabouraud's dextrose agar medium incubated at 25, 30 and 35°C yielded pure cultures of several colonies of a mould with an unusual aspect. Colonies were fast growing and appeared cinnamon brown, powdery to cottony near the center (Fig. 2A). Microscopic examination revealed

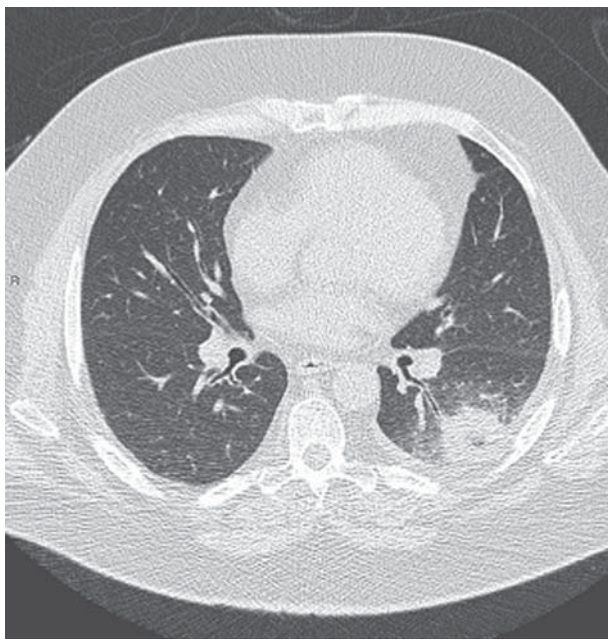


Fig. 1 Chest computed tomodensitometry showing the dense subpleural nodule with halo sign.

regular and septate hyphae with ovoid to pyriform conidia borne sessile or arising singly or in small groups from ampulliform stalks (Fig. 2B). Conidia, were finely to coarsely roughened and were hyaline to pale brown pigmented appearing orange brown in mass (Fig. 2C). Identification of the isolate was achieved through amplification and sequencing of both ITS rDNA and D1/D2 region of the 28S rDNA. Comparison of the nucleotide sequences of the isolate revealed 99.6 % (490 bp) on ITS and 100% similarity on D1/D2 (560 bp) with those of *M. thermophila* ex-type strain accessioned as UAMH 2474 in the University of Alberta Microfungus Collection and Herbarium, Edmonton, AB. The thermophilic character described for this species was also confirmed for our isolate (growth at 45, 50, 55 but not at 65°C). All bacterial, as well as fungal blood cultures initiated during this patient's hospitalization were negative. Antifungal susceptibility testing performed at the French National Reference Center for Mycoses and Antifungals (CNRMA, Institut Pasteur, Paris) according to the EUCAST standardized methodology [10] revealed high MICs against amphotericin B (6 µg/ml), caspofungin (16 µg/ml) and itraconazole (1 µg/ml) but low MICs against voriconazole (0.004 µg/ml) which was associated with a favourable outcome in our patient. However, a few months later, a relapse of the AML was noted and allogenic stem cell transplantation was scheduled. Prior to transplantation, resection of a segment of a lobe of the lung was performed to prevent invasive disease. To date, no relapse of the fungal infection has been observed.

Discussion

To test if positive GM assay results found with samples from our patient could have been due to cross-reactions with *M. thermophila* we employed a previously described protocol [3]. Briefly, fungal conidia of the isolate were suspended in 1 ml sterile distilled water. After vigorous agitation for 1 min, the suspension was centrifuged for 5 min at 10,000 g and the supernatant was collected for GM assay. Then 300 µl of the supernatant and each of two supplementary dilutions (1:10 and 1:100) were tested in the GM assay according to the manufacturer's instructions. Positive (*A. fumigatus*) and negative (*C. albicans*) controls were included in the experiment. All three test samples yielded positive GM results (index at 5.693, 5.237 and 2.370 respectively).

Myceliophthora thermophila is a saprophytic thermophilic mould widely found in the environment especially in self-heating environments such as compost or wood chip piles but it is an infrequent cause of disease in humans [11]. Colonies of this fungus grow rapidly at 35°C, and are flocculose to powdery with a typical cinnamon color in

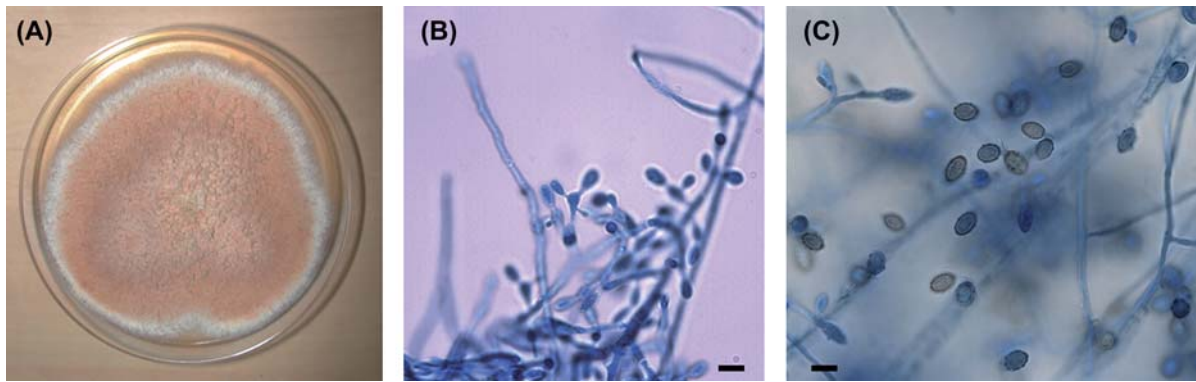


Fig. 2 (A) Colony morphology of *Myceliophthora thermophila* after 6 days culture at 30°C on Sabouraud's dextrose agar medium. (B) Microscopic morphology showing ovoid to pyriform conidia arising singly or in small groups from ampulliform stalks (Lactophenol cotton-blue staining). (C) Young paler conidia and mature, cinnamon brown, roughened conidia (Lactophenol cotton-blue staining). All scale bars 5 µm.

4 to 5 days. Microscopic examination revealed septate hyphae along with several obovoidal to pyriform conidia ($3.0\text{--}4.5 \times 4.5\text{--}11$ µm) arising singly or in small groups from conidiogenous cells. Smooth and pale when young, conidia are finely rough and exhibited a typical cinnamon to brown color when mature. Poor outcomes were associated with almost half of the five cases reported since 1992 [12–16]. Importantly, we confirmed previous findings of high MICs against amphotericin B and caspofungin, two antifungal drugs used in the management of IA [13]. However, to date, cross-reactivity with GM assay has not been reported. Future studies will have to determine the exact epitope that interacts with the *Aspergillus* GM assay.

In summary, this report underlines the pathogenic potential of *M. thermophila* in humans and identifies a new cause of cross-reaction with the GM assay. These findings highlight that the occurrence of positive *Aspergillus* GM results must be taken with caution in high-risk patients due to possible cross-reactivity with several emerging or rare fungal species. In this setting, misidentification of these invasive fungal infections could have major clinical consequences if a species exhibiting poor susceptibility to voriconazole is involved. Finally, from an epidemiological perspective, potential GM cross-reactivity must be considered in future studies including patients categorized as having probable IA using the GM as the only mycological criterion.

Nucleotide sequences have been included in Genbank database for the case isolate under accession numbers HQ676489 (ITS) and HQ676490 (D1/D2) and for the reference strain of *M. thermophila* (ex-type strain UAMH 2474), under numbers HQ724321 (ITS) and HQ724320 (D1/D2). The isolate has been deposited at the University of Alberta Microfungus Collection and Herbarium as UAMH 11479.

Acknowledgments

We acknowledge Dea Garcia-Hermoso and Eric Dannaoui (CNRMA, Institut Pasteur, Paris, France) for performing *in vitro* antifungal susceptibility testing of the isolate. We acknowledge Bernard Besse and Olivier Barre for their technical assistance.

Declaration of interest: The authors report no conflicts of interest. The authors alone are responsible for the content and writing of the paper.

References

- Mennink-Kersten MA, Donnelly JP, Verweij PE. Detection of circulating galactomannan for the diagnosis and management of invasive aspergillosis. *Lancet Infect Dis* 2004; **4**: 349–357.
- De Pauw B, Walsh TJ, Donnelly JP, *et al.* Revised definitions of invasive fungal disease from the European Organization for Research and Treatment of Cancer/Invasive Fungal Infections Cooperative Group and the National Institute of Allergy and Infectious Diseases Mycoses Study Group (EORTC/MSG) Consensus Group. *Clin Infect Dis* 2008; **46**: 1813–1821.
- Giacchino M, Chiapello N, Bezzio S, *et al.* *Aspergillus* galactomannan enzyme-linked immunosorbent assay cross-reactivity caused by invasive *Geotrichum capitatum*. *J Clin Microbiol* 2006; **44**: 3432–3434.
- Fekkar A, Brun S, D'Ussel M, *et al.* Serum cross-reactivity with *Aspergillus* galactomannan and cryptococcal antigen during fatal disseminated *Trichosporon dermatis* infection. *Clin Infect Dis* 2009; **49**: 1457–1458.
- Xavier MO, Pasqualotto AC, Cardoso IC, Severo LC. Cross-reactivity of *Paracoccidioides brasiliensis*, *Histoplasma capsulatum*, and *Cryptococcus* species in the commercial Platelia *Aspergillus* enzyme immunoassay. *Clin Vaccine Immunol* 2009; **16**: 132–133.
- Pineau S, Talarmin JP, Morio F, *et al.* Contribution of molecular biology and *Aspergillus* galactomannan antigen assay for the diagnosis of histoplasmosis. *Med Mal Infect* 2010; **40**: 541–543. [in French].
- Wheat LJ, Hackett E, Durkin M, *et al.* Histoplasmosis-associated cross-reactivity in the BioRad Platelia *Aspergillus* enzyme immunoassay. *Clin Vaccine Immunol* 2007; **14**: 638–640.

- 8 Cummings JR, Jamison GR, Boudreaux JW, et al. Cross-reactivity of non-*Aspergillus* fungal species in the *Aspergillus* galactomannan enzyme immunoassay. *Diagn Microbiol Infect Dis* 2007; **59**: 113–115.
- 9 Borrás R, Roselló P, Chilet M, et al. Positive result of the *Aspergillus* galactomannan antigen assay using bronchoalveolar lavage fluid from a patient with an invasive infection due to *Lichtheimia ramosa*. *J Clin Microbiol* 2010; **48**: 3035–3036.
- 10 Rodriguez-Tudela JL, Arendrup MC, Arikan S, et al. EUCAST Technical Note on the method for the determination of broth dilution minimum inhibitory concentrations of antifungal agents for conidia-forming moulds. *Clin Microbiol Infect* 2008; **14**: 982–984.
- 11 De Hoog GS, Guarro J, Gené J, Figueras MJ (Eds). *Atlas of Clinical Fungi*, 2nd ed. Utrecht, The Netherlands and the Rovira I Virgili University, Reus, Spain: Centraalbureau voor Schimmelcultures, 2000.
- 12 Bourbeau P, McGough DA, Fraser H, Shah N, Rinaldi MG. Fatal disseminated infection caused by *Myceliophthora thermophila*, a new agent of mycosis: case history and laboratory characteristics. *J Clin Microbiol* 1992; **30**: 3019–3023.
- 13 Destino L, Sutton DA, Helon AL, et al. Severe osteomyelitis caused by *Myceliophthora thermophila* after a pitchfork injury. *Ann Clin Microbiol Antimicrob* 2006; **5**: 21.
- 14 Farina C, Gamba A, Tambini R, Beguin H, Trouillet JL. Fatal aortic *Myceliophthora thermophila* infection in a patient affected by cystic medial necrosis. *Med Mycol* 1998; **36**: 113–118.
- 15 Tekkok IH, Higgins MJ, Ventureyra EC. Posttraumatic gas-containing brain abscess caused by *Clostridium perfringens* with unique simultaneous fungal suppuration by *Myceliophthora thermophila*: case report. *Neurosurgery* 1996; **39**: 1247–1251.
- 16 Weitzel N, Puskas F, Cleveland J, Levi ME, Seres T. Left ventricular assist device outflow cannula obstruction by the rare environmental fungus *Myceliophthora thermophila*. *Anesth Analg* 2009; **108**: 73–75.

This paper was first published online on Early Online on 27 May 2011.