

***Thelebolus microsporus* Mycelial Mats in the Trachea of Wild Brown Skua (*Catharacta antarctica lonnbergi*) and South Polar Skua (*C. maccormicki*) Carcasses**

Gerardo A. Leotta,¹ Jean A. Paré,^{2,7} Lynne Sigler,³ Diego Montalti,⁴ Germán Vigo,⁵ Miguel Petruccelli,⁶ and Enso H. Reinoso,¹ ¹ Cátedra de Micología Médica e Industrial, Facultad de Ciencias Veterinarias, Universidad Nacional de La Plata, Calle 118 y 60, La Plata (1900), Pcia. de Buenos Aires, Argentina, CC 296; ² Department of Surgical Sciences, School of Veterinary Medicine, University of Wisconsin, 2015 Linden Drive West, Madison, Wisconsin 53706, USA; ³ University of Alberta Microfungus Collection & Herbarium, Devonian Botanic Garden, Edmonton, Alberta, Canada T6G 2E1; ⁴ Dirección Nacional del Antártico, Cerrito N° 1248, Buenos Aires, Argentina; ⁵ Laboratorio de Investigaciones y Diagnóstico Bacteriológico, Facultad de Ciencias Veterinarias, Universidad Nacional de La Plata, Calle 118 y 60, La Plata (1900), Pcia. de Buenos Aires, Argentina; ⁶ Cátedra de Patología de Aves y Pilíferos, Facultad de Ciencias Veterinarias, Calle 118 y 60, Universidad Nacional de La Plata, La Plata (1900), Pcia. de Buenos Aires, Argentina; ⁷ Corresponding author (email: PareJ@svm.vetmed.wisc.edu).

ABSTRACT: Sixteen brown skuas (*Catharacta antarctica lonnbergi*) and seven South Polar skuas (*C. maccormicki*) were found dead near Boekella Lake, Hope Bay, Antarctica, in February 1997. Postmortem examination revealed conspicuous caseous, deep yellow fungal/mycelial mats or cores in the trachea of nine of 19 carcasses that were examined. These mycelial cores, highly suggestive of aspergillomas, completely occluded the tracheal lumen in four of these nine carcasses. *Thelebolus microsporus*, a psychrophilic ascomycetous fungus commonly isolated from skua dung and skua nesting material, was isolated in pure culture from these tracheal plugs. Awareness of pseudolesions resulting from *Thelebolus microsporus* profuse postmortem growth in the trachea of dead skuas will minimize potential confusion with aspergillosis when investigating causes of epornithics in Antarctica.

Key words: Case report, *Catharacta antarctica lonnbergi*, *Catharacta maccormicki*, necropsy, skua, *Thelebolus microsporus*, tracheal obstruction.

Skuas are large, gull-like polar birds belonging to the Stercorariidae (Cohen et al., 1997). The brown skua (*Catharacta antarctica lonnbergi*) is an Antarctic species and has a circumpolar distribution, while the South Polar skua (*C. maccormicki*) which breeds mainly on the Antarctic continent may be found north of the equator in winter. Skuas are effective predators, feeding on fish, crustaceans, and penguin eggs and chicks, but they will also scavenge carcasses and feed at sewage outlets (Trivelpiece et al., 1980; Pietz, 1987). Documented epornithics involving skuas are

rare (Howie et al., 1968; Parmelee et al., 1979) and very little is known about diseases of free-ranging skuas. In one outbreak of mortality in South Polar skuas, the cause of death could not be identified (Montalti et al., 1996). Aspergillosis is a respiratory tract infection of birds commonly involving or localizing in the trachea (Redig, 1993). While *Aspergillus* spp. is a major cause of fungal disease in wild shorebirds and seabirds (Friend, 1999), little is known about the prevalence of mycoses and fungal etiologic agents in free-ranging Antarctic avian species.

In February 1997, 16 brown and seven South Polar skuas were found dead near Boekella Lake, Hope Bay, Antarctica (63°4'S, 56°59'W). Clinical signs observed in a few birds found moribund included dyspnea, inability to fly, general weakness, and loss of a fear response to approaching humans. Nineteen carcasses were collected and frozen at -20 C, and complete necropsies were later performed in an attempt to determine the cause of death. Autolytic changes were present in all carcasses. Among the prominent findings were necrotic and/or fibrinous to caseous-looking, deep yellow masses in the trachea of seven birds (Fig. 1). These masses completely obstructed the tracheal lumen in four of these carcasses. The tracheal mucosa was sloughed in most birds, with deep reddish black areas present in the exposed submucosa. Other conspicuous findings



FIGURE 1. Cross sections of trachea from skua carcasses demonstrating thick, nodular, intraluminal *Thelebolus microsporus* mycelial mats admixed with sloughed necrotic mucosa.

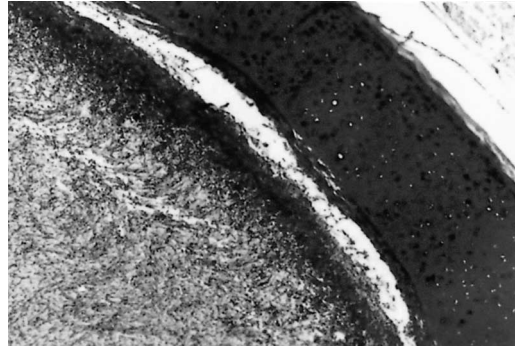


FIGURE 2. Dense, massive *Thelebolus microsporus* mycelial mat effacing the submucosa of the trachea and extending in the lumen. PAS stain, $\times 100$.

consisted of fibrinous pericarditis and thickening of air sacs and coelomic membranes with fibrinous adhesions in all birds. The gastrointestinal tracts were typically empty, except for some feathers, stones, and lichen. Tissues were collected, fixed in 10% neutral buffered formalin, and then stained with hematoxylin and eosin and with periodic acid-Schiff stain. Tissue samples submitted for bacteriology were cultured on 5% sheep's blood agar in a 10% CO₂ atmosphere and on McConkey agar. Sections of lung and trachea from all 19 carcasses were prepared and inoculated in chick embryos for virus isolation attempts. A direct fluorescent antibody technique (Chlamydia Direct IF, Bio Merieux Laboratory, Marcy L'Étoile, France) was used to test for *Chlamydia psittaci* in tissues. For *Mycoplasma* spp. isolation, tracheal mucosa swabs were incubated in Frey's liquid and solid medium at 37 C for 30 days. Wet mounts were prepared from tracheal lesions. For fungal isolation, lung and trachea tissue samples were inoculated onto Sabouraud agar containing yeast extract and chloramphenicol and incubated at 28 and 37 C.

Bacteriology and virology were negative. Mycoplasmal isolation attempts and a search for chlamydophilial antigen in tissues using the fluorescent antibody technique were unsuccessful. However, a slow-growing fungus was isolated in pure culture on agars incubated at 28 C. It was isolated from the trachea of all skuas in which necrotic yellow debris was demonstrated macroscopically but was not recovered from the trachea or lungs of any of

the birds in which the trachea appeared normal at necropsy. This fungus failed to grow at 37 C. It was identified as *Thelebolus microsporus* Kimbrough, a psychrophilic ascomycete, based on morphology and growth in culture. Autolytic changes severely hampered histopathologic evaluation of the tissues. There was convincing congestion and edema in pulmonary parenchyma of 11 birds. Fibrin deposition over coelomic serous membranes, liver capsule, and pericardium of most birds was accompanied by an inflammatory cell infiltrate. Microscopic examination of tracheal lesions revealed a massive quantity of septate hyphae streaming from denuded submucosa into the tracheal lumen (Fig. 2), and in many sections these hyphae extended transmurally through the tracheal rings. However, even when massive fungal growth was present, inflammatory cells could not be demonstrated in the submucosa and sloughed mucosa of the trachea, indicating that fungal growth occurred after death. Occasionally, hyphae were also seen in sections of severely autolytic pulmonary parenchyma, again without any associated inflammatory reaction. Postmortem results therefore suggested that most skuas died of fibrinous, most likely bacterial, serositis. Autolysis and field working conditions hindered establishment of a definitive etiologic diagnosis.

Lesions observed in tracheas of many birds were initially believed to have devel-

oped antemortem, causing the dyspnea observed in moribund birds. The yellowish caseous/necrotic masses were highly suggestive of aspergillomas. When septate hyphae were observed microscopically in wet mounts prepared from tracheal lesions, a tentative diagnosis of primary or secondary aspergillosis appeared logical and was only dismissed when *T. microsporus* was repeatedly isolated in the absence of *Aspergillus*. Histopathologically, the fungal hyphae invading the trachea superficially resembled those of *Aspergillus* sp., but lacked the dichotomous branching typically found in invasive *A. fumigatus* infections. Additionally, once identity of the fungus was established, reexamination of tracheal sections disclosed the presence of occasional ascospores.

Thelebolus microsporus (family Thelebolaceae) is a psychrophilic coprophilous ascomycete forming minute discoid apothecia (sexual fruiting structures) (Kobayashi et al., 1967). Three isolates from skua tracheas were deposited in the University of Alberta Microfungus Collection and Herbarium (UAMH) as UAMH 9625 (8894), UAMH 9626 (8890), and UAMH 9662 (8892) and identified by their growth habit in culture. Colonies on potato dextrose agar (PDA, Difco Laboratories Incorporated, Cambridge, UK) were approximately 7 cm in diameter after 20 days incubation at 5 C and were thin with little aerial mycelium, flat or slightly folded, and orange-brown in the center and cream or pale orange at the margin (Fig. 3a). Colonies on oatmeal salts agar (Weitzman and Silva-Hutner, 1967) appeared paler and thinner. The sexual structures (ascomata) developed abundantly on both media at 5 and 18 C, initially appearing as round to oval thin-walled cleistothecia, later becoming apothecoid and pale orange brown (Fig. 3b, c). Eight ascospores were formed within broadly cylindrical asci and were forcibly discharged from apothecoid ascomata onto the lid of the petri dish. Ascospores were 6–10 μm long by 3.5–6 μm wide and were obovate (egg-shaped) and

sometimes slightly flattened on one side (Fig. 3d). No other spore state was formed.

Thelebolus microsporus is a common fungus in the Antarctic ecosystem and has been isolated from soil within skua nesting areas; from dung of skuas, penguins, and petrels; from feathers, lichens, and moss; and from aquatic mud (Wicklowsky and Malloch, 1968; Montemartini Corte et al., 1993; Azmi and Seppelt, 1998). Soil, lichen, and moss are used as nesting material by skuas, suggesting an intimate relationship between the birds and the fungus. *Thelebolus microsporus* likely enters the bird via the digestive and respiratory tracts, because it has been isolated from tracheal and cloacal swabs of healthy skuas (Leotta, unpubl. data). *Thelebolus microsporus* grows optimally at 15 C and shows good growth at 0 C (Montemartini Corte et al., 1993). Our isolates grew well at 4 C but poorly at 25 C. We hypothesize that following death, a decrease in body temperature triggered *T. microsporus* spores, normally present in the trachea of some birds, to germinate and grow unchecked. The thick mycelial mats that result, encrusted in autolytic sloughed mucosa, could be easily misidentified as aspergillomas. The yellow or orange coloration of *T. microsporus* colonies simulated that of avian caseum and added to the deceit. Birds in which tracheal plugs were not found may not have been harboring *Thelebolus* spores in their trachea at the time of death. Because the trachea is filled with outside air, a cold and optimal *Thelebolus* growth temperature is probably reached earlier within it than in the rest of the carcass, which may explain the site specificity of these pseudolesions.

The authors wish to thank Instituto Antártico Argentino for providing logistic support to the authorities of Departamento de Biología de la Dirección Nacional del Antártico. We are especially grateful to Licenciata Nestor Coria and Veterinary Captain Mario Perez Cometo, for collecting dead birds and for his assistance and

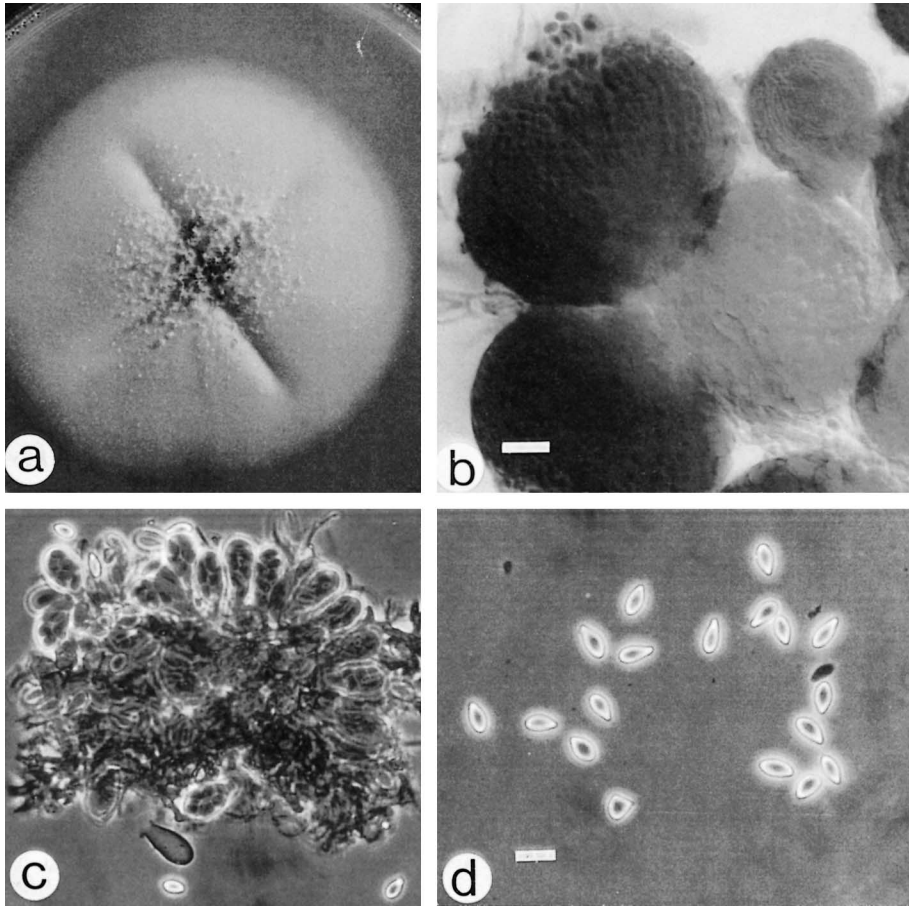


FIGURE 3. a. Colony of *Thelebolus microsporus* on potato dextrose agar after 20 days incubation at 5 C. b. Ascomata (sexual fruiting bodies) of *Thelebolus microsporus*. Bar = 10 μ m. c. Ascomata of *Thelebolus microsporus* showing asci containing ascospores. Bar = 12 μ m. d. *Thelebolus microsporus* ascospores. Bar = 10 μ m.

collaboration in Hope Bay, and to G. Martín, M. Mujica, J. Moroni, G. Praca, and R. Cerdá. Financial assistance to L. Sigler from Natural Sciences and Engineering Research Council of Canada is gratefully acknowledged.

LITERATURE CITED

- AZMI, O. R., AND R. D. SEPELT. 1998. The broad-scale distribution of microfungi in the Windmill Islands region, continental Antarctica. *Polar Biology* 19: 92–100.
- COHEN, B. L., A. J. BAKER, K. BLECHSCHMIDT, D. L. DITTMANN, R. W. FURNESS, J. A. GERWIN, A. J. HELBIG, J. DE KORTE, H. D. MARSHALL, R. L. PALMA, H.-U. PETER, R. RAMLI, I. SIEBOLD, M. S. WILLCOX, R. H. WILSON, AND R. M. ZINK. 1997. Enigmatic phylogeny of skuas (Aves: Stercorariidae). *Proceedings of the Royal Society of London B* 264: 181–190.
- FRIEND, M. 1999. Aspergillosis. In *Field manual of wildlife diseases, General field procedures and diseases of birds*, M. Friend and J. C. Franson (eds.). U.S. Geologic Survey, Biological Resources Division, Madison, Wisconsin, pp. 129–133.
- HOWIE, C. A., N. V. JONES, AND I. C. WILLIAMS. 1968. A report on the death of sheathbills, *Chionis alba* (Gmelin), at Signy Island, South Orkney Islands, during the winter of 1965. *British Antarctica Survey Bulletin* 18: 79–83.
- KOBAYASHI, Y., N. HIRATSUKA, R. P. KORF, K. TUBAKI, K. AOSHIMA, M. SONEDA, AND J. SUGIYAMA. 1967. Mycological studies of the Alaskan arctic. *Institute for Fermentation Annual Report* 3: 50–51.
- MONTALTI, D., N. R. CORIA, AND A. CURTOSI. 1996. Unusual deaths of subantarctic skuas *Catharacta*

- antarctica* at Hope Bay, Antarctica. *Marine Ornithology* 24: 39–40.
- MONTEMARTINI CORTE, A., G. CARETTA, AND G. DEL FRATE. 1993. Notes on *Thelebolus microporus* isolated in Antarctica. *Mycotaxon* 48: 343–358.
- PARMELEE, D. F., S. J. MAXSON, AND N. P. BERNSTEIN. 1979. Fowl cholera outbreak among brown skuas at Palmer Station. *Antarctic Journal* 14: 168.
- PIETZ, P. J. 1987. Feeding and nesting ecology of sympatric South Polar and brown skua. *The Auk* 104: 617–627.
- REDIG, P. T. 1993. Avian aspergillosis. *In* *Zoo and wild animal medicine, Current therapy* 3, M. Fowler (ed.). W.B. Saunders Company, Philadelphia, Pennsylvania, pp. 178–181.
- TRIVELPIECE, W., R. G. BUTLER, AND N. J. VOLKMAN. 1980. Feeding territories of brown skuas (*Catharacta lonnbergi*). *The Auk* 97: 669–676.
- WEITZMAN, I., AND M. SILVA-HUTNER. 1967. Non-keratinous agar media as substrates for the ascigerous state in certain members of the Gymnoascaceae pathogenic for man and animals. *Sabouraudia* 5: 335–340.
- WICKLOW, D. T., AND D. MALLOCH. 1971. Studies in the genus *Thelebolus*: Temperature optima for growth and ascocarp development. *Mycologia* 63: 118–131.

Received for publication 26 February 2001.