

CASE REPORTS

White Grain Mycetoma Caused by a *Cylindrocarpon* sp. in India

B. M. HEMASHETTAR,¹ B. SIDDARAMAPPA,² A. A. PADHYE,^{3*} L. SIGLER,⁴ AND F. W. CHANDLER⁵

Departments of Microbiology¹ and Dermatology, Venereology, and Leprology,² Jawaharlal Nehru Medical College, Belgaum, India; Mycotic Diseases Branch, Division of Bacterial and Mycotic Diseases, National Center for Infectious Diseases, Centers for Disease Control and Prevention, Atlanta, Georgia 30333³; The University of Alberta Microfungus Collection and Herbarium, Devonian Botanic Garden, University of Alberta, Edmonton, Alberta T6G 2E1, Canada⁴; and Department of Pathology, Medical College of Georgia, Augusta, Georgia 30912⁵

Received 9 June 2000/Returned for modification 12 July 2000/Accepted 12 August 2000

We describe a case of white grain eumycetoma of the foot of an Indian male caused by a slow-growing, poorly sporulating fungus that does not match any known agent of this infection. Histologic examination of a biopsy tissue specimen showed oval, lobular, white granules composed of hyaline, septate hyphae, and thick-walled chlamydo spores. Culture of granules from a draining sinus yielded compact, very-slow-growing, poorly sporulating colonies producing a strong reddish brown pigment that diffused into the medium. The fungus was identified as a *Cylindrocarpon* sp. based on the development of rare cylindrical conidia borne from solitary phialides lacking collarettes, in addition to chlamydo spores formed singly or in short chains.

CASE REPORT

A 57-year-old male patient from Belgaum, south India, had sustained a trauma by a thorn 10 to 12 years earlier. The thorn was removed but a pustule developed at the site some time after the injury. The pustule discharged serosanguineous fluid and eventually healed. Later, new lesions developed, and this process was repeated over a period of 11 years. In 1990, when first seen by the senior authors, the patient was admitted to the hospital with slight swelling of the left foot, pain, and draining sinuses and was diagnosed as having pale white grain eumycetoma based on histopathologic examination of the biopsy tissue specimen and isolation of a hyaline, hyphomycetous fungus that could not be identified at that time.

During his most recent hospital admission in June 1997, the left foot was swollen and the skin over the foot was darkly pigmented. There were three discharging sinuses, two on the dorsum and the third on the plantar aspect of the foot, and several scars were visible. The sinus openings were slightly elevated from the surrounding tissue, showing a small amount of discharge (Fig. 1). The foot was hard and woody to the touch. There were no signs of acute inflammation. A general physical examination was normal. The X-ray examination of the foot showed no bone involvement but showed soft tissue swelling. Routine clinical chemistry and hematological investigations and serology for human immunodeficiency virus were within normal limits.

After a thorough cleaning of the lesions, a Pasteur pipette was introduced into one of the sinuses and the fluid was aspirated. The aspirated material was rinsed in sterile saline and allowed to settle. A few creamy white, soft, white granules measuring 0.5 to 1.2 mm in diameter were observed. The granules were separated, washed in sterile saline, and when examined

microscopically in KOH mounts, showed hyaline, septate hyphae, and chlamydo spores. Several washed granules were cultured on plates of Sabouraud dextrose agar with chloramphenicol (Sab+C) incubated at room temperature (25 to 30°C). Fungal growth was apparent after 12 days of incubation. Colonies were slow growing, white, and downy, producing a light wine-reddish pigment which diffused into the medium. Microscopic examination of the slide culture preparations on potato dextrose agar after 3 weeks of incubation at 25°C showed sterile, septate, hyaline hyphae. Attempts to induce sporulation were unsuccessful. Two unstained histologic slides and a subculture were sent to one of us (A.A.P.) for further examination.

Histopathologic examination. The slides were stained by hematoxylin and eosin and Gomori's methenamine silver stain procedures. The overlying epidermis was intact and of normal thickness. In the deep dermis and subcutaneous tissue, there were multifocal abscesses and burrowing sinus tracts, surrounded by varying numbers of epithelioid histiocytes and multinucleated giant cells. The granulomatous component blended imperceptibly with peripheral granulation tissue that was infiltrated with mixed inflammatory cells. The suppurative centers of abscesses and sinus tracts contained discrete, spherical, oval and lobular mycotic granules, 0.5 to 1.0 mm in diameter, composed of compact, interwoven, hyaline hyphae and fewer vesicular, thick-walled chlamydo spores up to 15 μ m in diameter. Hyphae that formed the granules were branched, septate, 4.0 to 6.5 μ m wide, and often radially oriented, especially at the periphery of the granules where fungal elements, including chlamydo spores, were more numerous and compact. The central portions of some of the granules consisted of a loose network of disintegrated, poorly stained, randomly oriented hyphae and intact or degenerated inflammatory cells. Cement-like substance was not observed within the matrix of the granules (Fig. 2). Each granule was entirely or partially bordered by brightly eosinophilic, dentate to smoothly contoured, Splendore-Hoeppli material. Mycelial elements sometimes extended into this material, which was intimately

* Corresponding author. Mailing address: Mycotic Diseases Branch, Mail Stop G-11, Centers for Disease Control and Prevention, Atlanta, GA 30333. Phone: (404) 639-3749. Fax: (404) 639-3546. E-mail: aap1@cdc.gov.

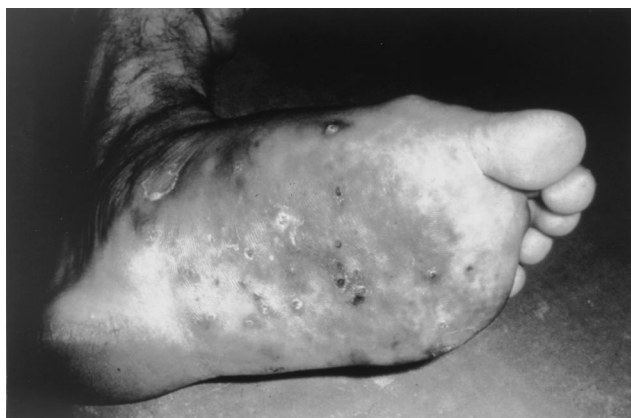

FIG. 1. Swollen left foot of the patient, showing discharging sinuses.

surrounded by intact neutrophils. There was no histologic evidence of a coexisting infection, and foreign materials such as thorns were not detected either within or near the granules.

Mycology. The isolate was given accession number CDC 534-96. Colonies on Sabouraud dextrose agar were slow growing, raised in the center, downy, and white at first, becoming grayish buff after 2 weeks at 25°C. They measured 6 to 7.5 mm in diameter after 2 weeks at 25°C and produced reddish brown pigment on the reverse of the colonies that diffused into the medium. Colonies at 37°C measured 3.5 to 4.5 mm in diameter. The isolate did not grow at 40°C. Microscopic examination of slide culture preparations on potato dextrose agar after 3 weeks at 25°C showed hyaline, septate, branched hyphae 2.5 to 5.0 µm wide, producing chlamydospores but devoid of conidia.

The isolate was also sent for additional testing to the University of Alberta Microfungus Collection and Herbarium, where it was given accession number UAMH 8935. Culture on potato dextrose agar (Difco Laboratories, Detroit, Mich.) at room temperature revealed restricted, irregular, raised, dirty white to grayish-buff colonies demonstrating reddish brown diffusing pigment (Fig. 3). The isolate was grown on media including cereal agar, oatmeal salts agar, V-8 juice agar, and Takashio agar (all prepared in-house according to recipes in reference 10) to promote conidial formation. Conidiation occurred sparsely and best on Takashio and oatmeal salts agars

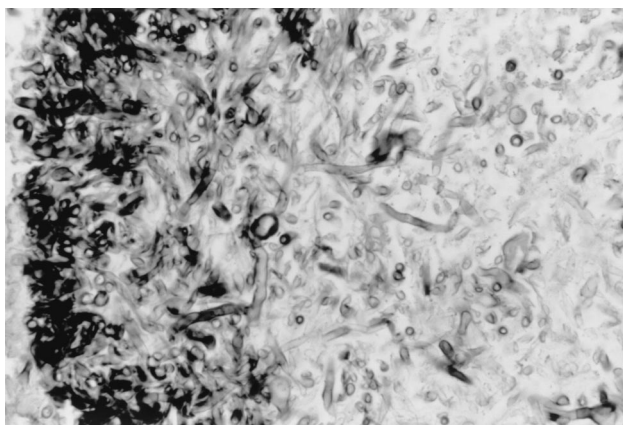


FIG. 2. Section of granule showing a loose network of branched, septate hyphae and vesicular chlamydospores in peripheral area of the granule, Gomori methenamine silver stain. Magnification, ×250.

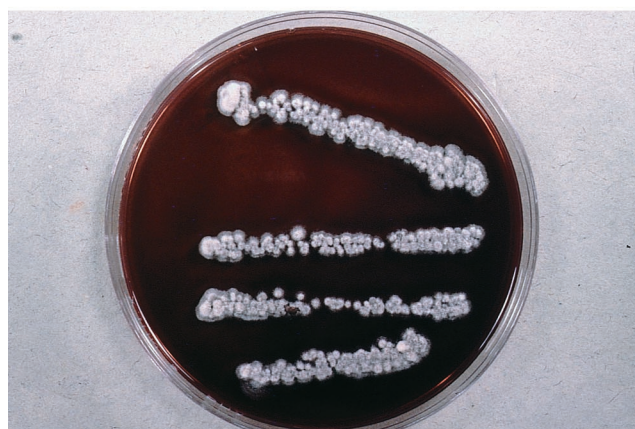
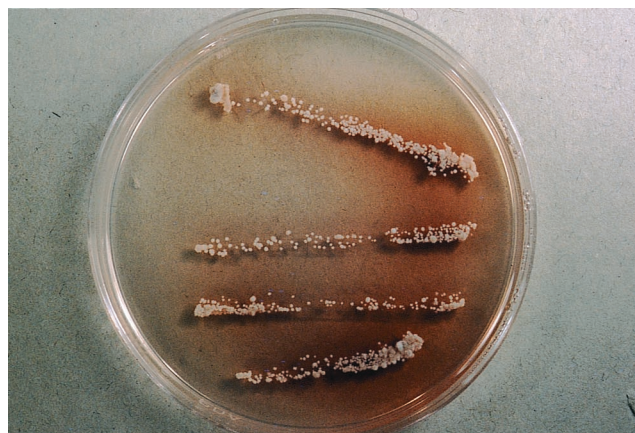
FIG. 3. Colony of *Cylindrocarpon* sp. (UAMH 8935) on potato dextrose agar incubated at room temperature. (Top) After 11 days, showing presence of some diffusible pigment. (Bottom) Same plate after 3 months, showing strong reddish brown diffusing pigment.

after prolonged incubation (3 to 14 weeks at room temperature) and consisted of zero- to one-septate, cylindrical, sometimes slightly curved, conidia produced from unbranched septate phialides without collarettes (Fig. 4A). Single-celled conidia measured 9 to 14 µm long and 2 to 2.5 µm wide, and two-celled conidia measured 17 to 25 µm long by 2 to 3 µm wide. Chlamydospores were mostly solitary, intercalary or terminal, and were subglobose, smooth to slightly roughened (Fig. 4B).

Discussion. Eumycetoma is a long-term, slowly progressing infection that develops in individuals usually following traumatic implantation of fungus-contaminated plant material. Thirteen species of fungi (3 belonging to the Ascomycota and 10 belonging to the Deuteromycota) are known to cause white grain eumycetoma (12). Some of these fungi can be difficult to identify in vitro because of poor sporulation, and we know little about their plant hosts, on which they may potentially produce conidia of their life cycle. Host response to the presence of the fungus and adaptation to growth in human tissue (including bone) may induce phenotypic changes, resulting in isolates which appear atypical in culture. Similar aberrant morphology characterized by absence of conidia and restricted colonies has been observed particularly among isolates of *Aspergillus fumigatus* and other species of *Aspergillus* recovered from patients with chronic infections (13; L. Sigler, M. A. Viviani, U.

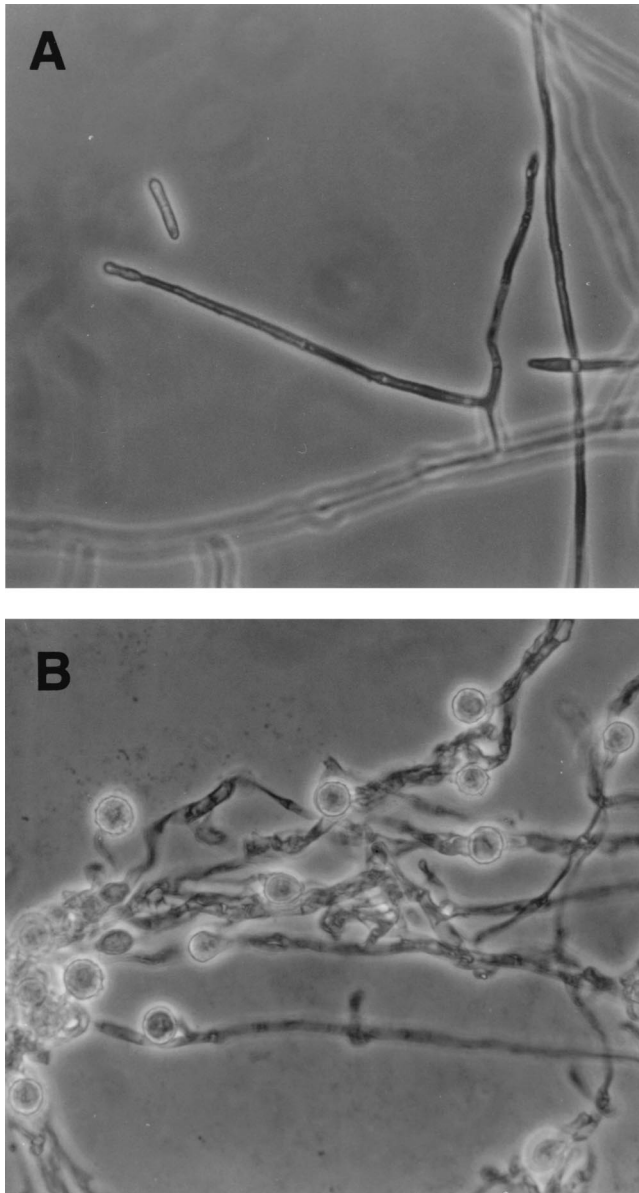


FIG. 4. Microscopic morphology of *Cy lindrocarpon* sp. (UAMH 8935). (A) Septate phialide and cylindrical conidia that formed on oatmeal salts slide culture after 14 weeks. (B) Chlamydo spores formed on Takashio agar after 22 weeks. Magnification, $\times 580$.

Magrini, R. Epis, V. Fregoni, A. Grancini, and A. Pastorini, International Society for Human and Animal Mycology, abstr. P396, 1997).

Our slow-growing, poorly sporulating fungus did not match any of the previously reported agents of white grain eumycetoma that have been reported from India during the last 20 years (1979 to 1998): *Acremonium falciforme* (15), *Acremonium kiliense* (15), *Acremonium recifei* (11), *Polycyrtella hominis* (3), and *Pseudallescheria boydii* (9, 14, 15). It appeared most similar to *Cy lindrocarpon cyanescens* (7) Sigler, reported from a single case of mycetoma involving a Dutch immigrant (5, 7, 17). Like their *Fusarium* relatives, *Cy lindrocarpon* species are anamorphs of ascomycetes belonging to the Hypocreaceae (teleomorph *Nectria*) and are cosmopolitan soil- and plant-associated fungi (6, 8, 13). They form straight or curved multicelled macroconidia having rounded ends, one- or two-celled micro-

conidia, and sometimes chlamydo spores. *Cy lindrocarpon* species have been reported twice previously as incitants of white grain eumycetoma. In both instances, the case isolates expressed atypical morphologies, demonstrating slow growth and few conidia. The first case involved the right foot of a 56-year-old Indonesian man diagnosed in The Netherlands (5) in which the causal agent was identified originally as *Phialophora cyanescens* (7). In 1991, Zoutman and Sigler reported a Canadian case involving an immigrant from Antigua in which the case isolate was identified as an atypical *Cy lindrocarpon destructans* (17). They also examined the ex-type strain of *Phialophora cyanescens* and argued that it was more similar to species of *Cy lindrocarpon* in having cylindrical phialides with nonflaring collarettes than to species of *Phialophora*, which are usually darkly pigmented and often have distinct collarettes. Even though *P. cyanescens* did not produce macroconidia like other species of *Cy lindrocarpon*, Zoutman and Sigler (18) transferred it to the genus *Cy lindrocarpon* as *C. cyanescens* based on similar placement of some species that rarely produce macroconidia within the genus *Fusarium*.

Our case isolate appeared highly similar to *C. cyanescens* in its strong production of reddish brown diffusible pigment and restricted growth. However, *C. cyanescens*, represented only by the ex-type strain (UAMH 5865 = CBS 518.82) and only one other isolate, produces small oval conidia measuring 4 to 7.5 μm by 2 to 3 μm from cylindrical phialides with nonflaring collarettes and chains of swollen chlamydo spores that may aggregate in clusters (6, 7, 17). In contrast, the chlamydo spores of our case isolate were mostly solitary, and the conidia were longer (9 to 25 μm), cylindrical, and one-septate. Conidia of similar shape and dimensions arising from simple phialides were described for *Cy lindrocarpon tenue* (2), but some isolates of this species demonstrate complex penicillate or verticillate branching, and the species has been reassigned to the genus *Cy lindrocladium* (16).

The species of *Cy lindrocarpon* appear similar in tissue but appear to differ in invasive ability, although the data are limited. No invasion of bone was noted in the present case or in the case concerning *C. cyanescens* (5); in contrast, *C. destructans* caused lytic bone destruction of the tarsals and the base of the third metatarsal (17). Granules produced by the *Cy lindrocarpon* species cannot be distinguished from each other, nor can they be differentiated from those of *P. boydii*, the *Acremonium* spp., and *Fusarium verticillioides* (= *F. moniliforme*) without cultural or immunofluorescence studies (1, 4). Generally, however, the granules of the *Cy lindrocarpon* species differed from those of *P. boydii* by having less prominent, fewer, and smaller chlamydo spores (4).

The role of antifungal therapy in treatment of *Cy lindrocarpon* mycetoma is unclear. The Indonesian patient with *C. cyanescens* mycetoma was treated initially with potassium iodide, followed by complete surgical debridement of the infected area. Postsurgery, the patient was treated with ketoconazole (20 mg/kg of body weight/day) for 12 months. However, 1 year after discontinuation of the treatment with ketoconazole, the treatment had to be resumed. The patient with *C. destructans* mycetoma of 12 years' duration declined any systemic antifungal therapy, although he had occasional drainage from the sinus tracts. In the present case, the infection, also of 10 to 12 years' duration, has been progressing very slowly. The patient was treated with oral ketoconazole (400 mg/day) for 10 weeks without any sign of appreciable clinical improvement. Therapy was discontinued because of the cost factor. The patient refused surgical intervention.

REFERENCES

1. **Ajello, L., A. A. Padhye, F. W. Chandler, M. R. McGinnis, L. Morganti, and F. Alberici.** 1985. *Fusarium moniliforme*, a new mycetoma agent: restudy of a European case. *Eur. J. Epidemiol.* **1**:5–10.
2. **Booth, C.** 1966. The genus *Cylindrocarpon*. *Mycol. Papers* **104**:1–56.
3. **Campbell, C. K.** 1987. *Polycytella hominis* gen. et sp. nov., a cause of human pale grain mycetoma. *J. Med. Vet. Mycol.* **25**:301–305.
4. **Chandler, F. W., and J. C. Watts.** 1987. Pathologic diagnosis of fungal infections. American Society of Clinical Pathologists, Chicago, Ill.
5. **De Bruyn, H. P., J. M. Broekman, G. A. de Vries, A. H. Klokke, and J. M. Greep.** 1985. Een patient met eumycetoma in Nederland. *Ned. Tijdschr. Geneesk.* **129**:1099–1101.
6. **De Hoog, G. S., and J. Guarro.** 1995. Atlas of clinical fungi. Centraalbureau voor Schimmelcultures, Baarn, The Netherlands.
7. **De Vries, G. A., G. S. de Hoog, and H. P. de Bruyn.** 1984. *Phialophora cyaneascens* sp. nov. with *Phaeosclera*-like synanamorph, causing white-grain mycetoma in man. *Antonie Leeuwenhoek J. Microbiol.* **50**:149–153.
8. **Domsch, K. H., W. Gams, and T. H. Anderson.** 1993. Compendium of soil fungi. IHW-Verlag, Eching, Germany. [Reprint of 1980 edition.]
9. **Joshi, K. R., A. Sanghvi, M. C. R. Vyas, and J. C. Sharma.** 1987. Etiology and distribution of mycetoma in Rajasthan, India. *Indian J. Med. Res.* **85**:694–698.
10. **Kane, J., R. C. Summerbell, L. Sigler, S. Krajdien, and G. Land.** 1997. Laboratory handbook of dermatophytes. A clinical guide and laboratory manual of dermatophytes and other filamentous fungi from skin, hair and nails. Star Publishing Co., Belmont, Calif.
11. **Koshi, G., A. A. Padhye, L. Ajello, and F. W. Chandler.** 1979. *Acremonium recifei* as an agent of mycetoma in India. *Am. J. Trop. Med. Hyg.* **28**:692–696.
12. **Padhye, A. A., and M. R. McGinnis.** 1999. Fungi causing eumycotic mycetoma, p. 1318–1326. In P. R. Murray, E. J. Baron, M. A. Pfaller, F. C. Tenover, and R. H. Tenover (ed.), *Manual of clinical microbiology*, 7th ed. American Society for Microbiology, Washington, D.C.
13. **Sigler, L., and M. J. Kennedy.** 1999. *Aspergillus, Fusarium* and other opportunistic moniliceous fungi, p. 1212–1241. In P. R. Murray, E. J. Baron, M. A. Pfaller, F. C. Tenover, and R. H. Tenover (ed.), *Manual of clinical microbiology*, 7th ed. American Society for Microbiology, Washington, D.C.
14. **Singh, H.** 1979. Mycetoma in India. *Indian J. Surg.* **41**:577–597.
15. **Venugopal, P. V., and T. V. Venugopal.** 1995. Pale grain eumycetomas in Madras. *Aust. J. Dermatol.* **36**:149–151.
16. **Watanabe, T.** 1994. *Cylindrocladium tenue* comb. nov. and two other *Cylindrocladium* species isolated from diseased seedlings of *Phellodendron amurense* in Japan. *Mycologia* **86**:151–156.
17. **Zoutman, D. E., and L. Sigler.** 1991. Mycetoma of the foot caused by *Cylindrocarpon destructans*. *J. Clin. Microbiol.* **29**:1855–1859.